


Trichiasis surgery for trachoma

Third Edition



World Health
Organization

Trichiasis surgery for trachoma

Third edition



**World Health
Organization**

Trichiasis surgery for trachoma, third edition

ISBN 978-92-4-008924-2 (electronic version)

ISBN 978-92-4-008925-9 (print version)

© **World Health Organization 2024**

Some rights reserved. This work is available under the Creative Commons Attribution-NonCommercial-ShareAlike 3.0 IGO licence (CC BY-NC-SA 3.0 IGO; <https://creativecommons.org/licenses/by-nc-sa/3.0/igo>).

Under the terms of this licence, you may copy, redistribute and adapt the work for non-commercial purposes, provided the work is appropriately cited, as indicated below. In any use of this work, there should be no suggestion that WHO endorses any specific organization, products or services. The use of the WHO logo is not permitted. If you adapt the work, then you must license your work under the same or equivalent Creative Commons licence. If you create a translation of this work, you should add the following disclaimer along with the suggested citation: “This translation was not created by the World Health Organization (WHO). WHO is not responsible for the content or accuracy of this translation. The original English edition shall be the binding and authentic edition”.

Any mediation relating to disputes arising under the licence shall be conducted in accordance with the mediation rules of the World Intellectual Property Organization (<http://www.wipo.int/amc/en/mediation/rules/>).

Suggested citation. Trichiasis surgery for trachoma, third edition. Geneva: World Health Organization; 2024. Licence: CC BY-NC-SA 3.0 IGO.

Cataloguing-in-Publication (CIP) data. CIP data are available at <https://iris.who.int/>.

Sales, rights and licensing. To purchase WHO publications, see <https://www.who.int/publications/book-orders>. To submit requests for commercial use and queries on rights and licensing, see <https://www.who.int/copyright>.

Third-party materials. If you wish to reuse material from this work that is attributed to a third party, such as tables, figures or images, it is your responsibility to determine whether permission is needed for that reuse and to obtain permission from the copyright holder. The risk of claims resulting from infringement of any third-party-owned component in the work rests solely with the user.

General disclaimers. The designations employed and the presentation of the material in this publication do not imply the expression of any opinion whatsoever on the part of WHO concerning the legal status of any country, territory, city or area or of its authorities, or concerning the delimitation of its frontiers or boundaries. Dotted and dashed lines on maps represent approximate border lines for which there may not yet be full agreement.

The mention of specific companies or of certain manufacturers' products does not imply that they are endorsed or recommended by WHO in preference to others of a similar nature that are not mentioned. Errors and omissions excepted, the names of proprietary products are distinguished by initial capital letters.

All reasonable precautions have been taken by WHO to verify the information contained in this publication. However, the published material is being distributed without warranty of any kind, either expressed or implied. The responsibility for the interpretation and use of the material lies with the reader. In no event shall WHO be liable for damages arising from its use.

Contents

Acknowledgements	vi
Abbreviations and acronyms	vii
List of figures.	viii
Overview.	x

Part One

For trainers and trainees

1. Introduction and overall objectives	1
2. The anatomy of the eye and the eyelid	2
2.1 The eye	2
2.2 The eyelid	2
3. Trachoma and its effect on the eye	4
3.1 Trachoma	4
3.2 Inflammation	4
3.3 Entropion	4
3.4 Trachomatous trichiasis (TT)	6
3.5 Corneal scarring	6
4. History of and examination for upper eyelid trichiasis and entropion	7
4.1 Questions to help identify someone who may have TT	7
4.2 Examination of the eyelid	7
4.3 Examination of the cornea for opacity	8
4.4 Examination for defective eyelid closure.	8
5. Indications for eyelid surgery	9
5.1 Definite indications for TT surgery	9
5.2 Contraindications to performing TT surgery in the community	9
6. Fitness of patients for surgery	10
6.1 Questions about general fitness.	10
7. Facilities and surgical materials	11
7.1 Facilities required	11
7.2 Surgical materials	11

8.	Sterilization	13
8.1	Principles of sterility	13
8.2	Definition of sterility	14
9.	Preparation	15
9.1	Preoperative patient preparation	15
9.2	Applying the local anaesthetic drops	16
9.3	Sterile preparation of the surgeon's (and assistant's) hands and the patient's skin ..	17
10.	Injecting local anaesthetic	18
10.1	Keeping the lidocaine in the bottle sterile	18
10.2	The injection	18
11.	Surgical procedure	20
11.1	Bilamellar tarsal rotation procedure	20
11.1.1	Stabilizing the eyelid	21
11.1.2	Creating the incision	22
11.1.3	Suturing the eyelid	24
11.2	Posterior lamellar tarsal rotation (modified Trabut) procedure	37
11.2.1	Placing the traction suture	37
11.2.2	Stabilizing the upper eyelid on to the Trabut plate	38
11.2.3	Making the incision	40
11.2.4	Dissecting the eyelid margin fragment	42
11.2.5	Suturing the eyelid margin fragment	44
11.3	Possible surgical difficulties	50
11.4	Applying the antibiotic and dressing	51
11.5	Give analgesic tablets and inform patients about follow up	51
11.6	Safe disposal of sharps	51
11.7	Disinfecting, cleaning and sterilizing the instruments	51
12.	Postoperative care	52
12.1	At day 1: Check the wound and eyelid correction	52
12.2	At day 8–14: Remove the sutures	52
12.3	At 6 weeks to 6 months	53
13.	Results	54

Part Two For Trainers

14. Introduction	55
14.1 Objectives	55
14.2 Who should be trained?	55
14.3 Expected training	56
15. Final assessment of TT surgeons	57
15.1 Using this section	57
15.2 Qualifications for certification	57
15.3 Knowledge and procedures to be assessed.....	57
15.4 Before surgery.....	57
15.5 Sterilization of equipment before use	58
15.6 Examination of the patient	58
15.7 Preoperative preparation	59
15.8 Injecting anaesthetic	60
15.9 Bilamellar tarsal rotation procedure	61
15.10 Posterior lamellar tarsal rotation (modified Trabut) procedure	62
15.11 Postoperative care	64
15.12 Use of the checklist	64
16. Checklist of procedures for certification of a surgeon in bilamellar tarsal rotation	65
17. Checklist of procedures for certification of a surgeon in posterior lamellar tarsal rotation (modified Trabut)	69
Bibliography	73

Acknowledgements

The World Health Organization (WHO) is grateful to the following individuals who contributed to the preparation of the third edition of this publication.

Main contributors

Amir B. Kello* (Expanded Special Project for Elimination of Neglected Tropical Diseases, WHO Regional Office for Africa, Brazzaville, Congo), Shannath L. Merbs* (Department of Ophthalmology and Visual Sciences, University of Maryland School of Medicine, Baltimore (MD), United States of America [USA]), Serge Resnikoff (School of Optometry and Vision Science, University of New South Wales, and Brien Holden Vision Institute, Sydney (NSW), Australia, and Organization pour la Prévention de la Cécité, Paris, France), Sheila K. West (Dana Center for Preventative Ophthalmology, Wilmer Eye Institute, Johns Hopkins Medicine, Baltimore (MD), USA), Silvio Paolo Mariotti (Eye and Vision Care, WHO headquarters, Geneva, Switzerland), Anthony W. Solomon (Global Neglected Tropical Diseases Programme, WHO, Geneva, Switzerland).

*Contributed equally.

Illustrations are reproduced with permission from Tim Phelps (Department of Art as Applied to Medicine, Johns Hopkins Medicine, Baltimore (MD), USA), with some images provided by courtesy of Shannath Merbs, Seydou Bakayoko (Institut d'Ophtalmologie Tropicale d'Afrique, University of the Sciences, Techniques and Technologies of Bamako, Bamako, Mali), Amir B. Kello and Emily Gower (University of North Carolina, Chapel Hill (NC), USA).

Reviewers

Balgesa Elkheir Elshafie (Federal Ministry of Health, Khartoum, Sudan), Patrick Massae (Huruma Hospital, Mkuu, United Republic of Tanzania), Caleb Mpyet (University of Jos, Jos, Nigeria), Fasahah Taleo (WHO Country Office, Port Vila, Vanuatu).

Financial acknowledgement

The Fred Hollows Foundation and the United States Agency for International Development financially supported the development of this publication.

Abbreviations and acronyms

BLTR	bilamellar tarsal rotation
PLTR	posterior lamellar tarsal rotation
TT	trichomatous trichiasis
WHO	World Health Organization

List of figures

1. Anatomy of the eye
2. Normal eyelid margin and eyelid margin with entropion
3. Applying a local anaesthetic drop
4. Injecting local anaesthetic
5. Position of surgeon and patient
6. Bilamellar tarsal rotation procedure: eyelid stabilization
7. Bilamellar tarsal rotation procedure: incision
8. Bilamellar tarsal rotation procedure: incised eyelid and parts
9. Bilamellar tarsal rotation procedure: spacing of the sutures
10. Bilamellar tarsal rotation procedure: placing the centre suture in the eyelid margin fragment
11. Bilamellar tarsal rotation procedure: placing the centre suture in the larger fragment
12. Bilamellar tarsal rotation procedure: continuing the centre suture
13. Bilamellar tarsal rotation procedure: completing the centre suture
14. Bilamellar tarsal rotation procedure: placing the second suture
15. Bilamellar tarsal rotation procedure: first two sutures in place
16. Bilamellar tarsal rotation procedure: placement of third suture
17. Bilamellar tarsal rotation procedure: third suture in place
18. Bilamellar tarsal rotation procedure: tying sutures to produce a slight overcorrection
19. Examples of correct eyelid surgery outcomes
20. Examples of eyelids with surgical problems
21. Bilamellar tarsal rotation procedure: sutures knotted and cut
22. Posterior lamellar tarsal rotation (modified Trabut) procedure: placement of traction suture
23. Posterior lamellar tarsal rotation (modified Trabut) procedure: placing the suture over the Trabut plate
24. Posterior lamellar tarsal rotation (modified Trabut) procedure: securing the traction suture
25. Posterior lamellar tarsal rotation (modified Trabut) procedure: incision through conjunctiva and tarsal plate
26. Posterior lamellar tarsal rotation (modified Trabut) procedure: cutting with scissors
27. Posterior lamellar tarsal rotation (modified Trabut) procedure: dissection of eyelid fragment
28. Posterior lamellar tarsal rotation (modified Trabut) procedure: dissection of the larger fragment

29. Posterior lamellar tarsal rotation (modified Trabut) procedure: centre suture in eyelid margin fragment
30. Posterior lamellar tarsal rotation (modified Trabut) procedure: centre suture in larger fragment
31. Posterior lamellar tarsal rotation (modified Trabut) procedure: completing the centre suture
32. Posterior lamellar tarsal rotation (modified Trabut) procedure: starting and completing the second suture
33. Posterior lamellar tarsal rotation (modified Trabut) procedure: third suture
34. Posterior lamellar tarsal rotation (modified Trabut) procedure: pulling sutures and guiding fragment
35. Posterior lamellar tarsal rotation (modified Trabut) procedure: tying knots
36. Posterior lamellar tarsal rotation (modified Trabut) procedure: sutures knotted and cut

Overview

The first edition of this manual, containing information about the bilamellar tarsal rotation procedure for entropion trichomatous trichiasis (TT), was published by the World Health Organization (WHO) in 1993.

The second edition, published by WHO in 2015, updated the original material on the bilamellar tarsal rotation procedure, and incorporated material from two other manuals on the posterior lamellar tarsal rotation (modified Trabut) procedure and the final assessment of candidate TT surgeons.

This third edition updates the definition of TT to that agreed at the fourth Global Scientific Meeting on Trachoma (Geneva, 27–29 November 2018), adds a description about how to examine for entropion, refines the lists of instruments and consumables required for surgery, expands and improves the guidance on post-operative care, includes updated illustrations, refines the presentation throughout and removes redundant material.

The manual is designed to provide specific information for TT trainers who are training others to undertake surgery for TT. It is divided into two parts. Part One covers the specific skills required for training TT surgeon candidates and serves as a resource document. Each section begins with one or more specific learning objectives; most include practice exercises. Trainers can use this manual as a guide for creating training presentations, use it in other ways to assist in training, or elect to have trainees read the material directly. The manual contains both knowledge that should be imparted during training and a description of the skills to be developed and assessed during practice and surgery sessions. Part Two is designed **only** for the trainers of the surgeon trainees and covers selection and final assessment of the trainees.

Part One

For trainers and trainees

1. Introduction and overall objectives

Part One of this manual provides specific details on training potential TT surgeons to undertake bilamellar tarsal rotation and/or posterior lamellar tarsal rotation (modified Trabut) procedures to correct TT.

The overall LEARNING OBJECTIVES FOR PART ONE are:

- (a) To be able to identify patients who require surgery for TT
- (b) To be able to perform successful bilamellar tarsal rotation and/or posterior lamellar tarsal rotation (modified Trabut) procedures to correct TT
- (c) To be able to assess results and manage complications of the bilamellar tarsal rotation and/or posterior lamellar tarsal rotation (modified Trabut) procedures

2. The anatomy of the eye and the eyelid

LEARNING OBJECTIVE: TO BE ABLE TO CORRECTLY NAME THE PARTS OF THE EYE AND THE EYELID

2.1 The eye (Fig. 1a)

- (a) The CORNEA is the clear window in the front of the eye.
- (b) The CONJUNCTIVA is a thin transparent layer covering the white part of the eye (sclera) and the inner parts of the eyelid.

2.2 The eyelid (Fig. 1b)

The EYELASHES come from roots 2 mm deep. They emerge just above the EYELID MARGIN in front of the grey line, and normally point away from the cornea. In normal upper eyelids, the eyelid margin is visible beneath the eyelashes at the edge of the eyelid (Fig. 2a). In eyes with entropion, the eyelid margin is often not visible as it, and the base of the eyelashes, are tucked behind the eyelid (Figs 1c and 1d).

- (a) The SKIN covers the outer surface of the eyelid.
- (b) The orbicularis MUSCLE lies under the skin.
- (c) The TARSAL PLATE is a thick, fibrous layer, which lies under the muscle and keeps the eyelid stiff. It is 1 cm high in the upper eyelid.
- (d) The CONJUNCTIVA is a shiny transparent layer, which covers the inner surface of the eyelid and goes onto the white part of the eye. Normally vessels are seen in the conjunctiva. The conjunctiva covering the upper eyelid tarsal plate may be partially or totally replaced by scarring, white stellate scars, or fibrous bands in cases of severe scarring.
- (e) The PUNCTUM is a hole at the nasal end on the edge of each eyelid (upper and lower), through which tears drain into the nose.

PRACTICE: TRAINEES WILL OBSERVE THE PARTS OF THE EYE IN EACH OTHER AND PRACTICE EVERTING THE EYELID TO OBSERVE THE TARSAL CONJUNCTIVA.

Fig. 1. Anatomy of the eye

Fig. 1a.

Photograph of a normal eye

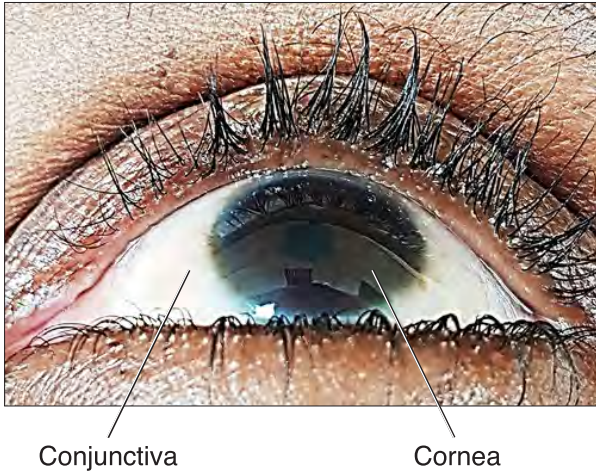

Fig. 1b.

Drawing of a sagittal section of a normal eye

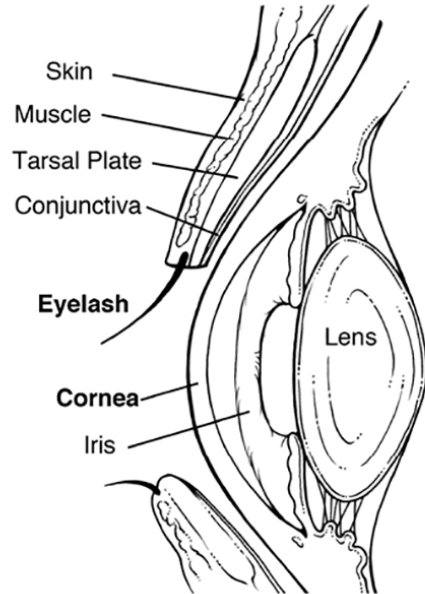


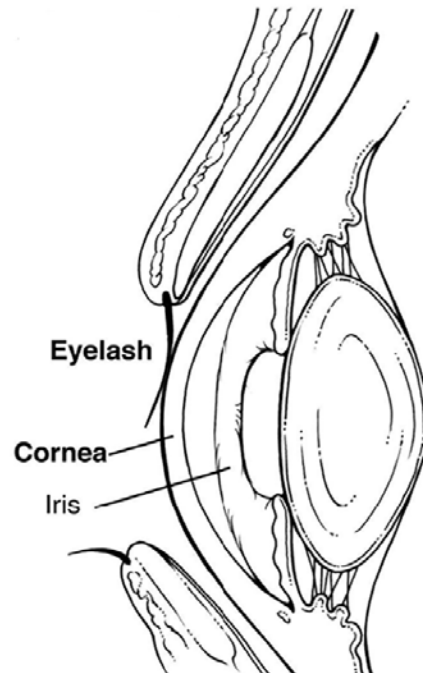
Fig. 1c.

Photograph of an eye with TT (arrow)

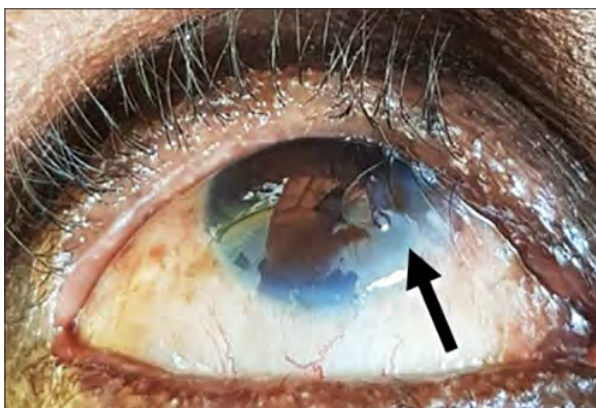

Fig. 1d.

Drawing of a sagittal section of an eye with TT



3. Trachoma and its effect on the eye

LEARNING OBJECTIVE: TO BE ABLE TO DESCRIBE TRACHOMA AND HOW IT DEVELOPS

3.1 Trachoma

Trachoma is an infectious disease caused by a bacterium, *Chlamydia trachomatis*. Trachoma usually starts in childhood, even as early as the first year of life. The disease is characterized by repeated episodes of ocular *C. trachomatis* infection throughout childhood and early adulthood.

3.2 Inflammation

Active trachoma is an inflammatory process that involves the tarsal conjunctiva and tarsal plate, which are seen on eversion of the upper eyelid. Inflammation is characterized by the formation of follicles, which are round lumps or spots that are paler than the surrounding tissue. Follicles contain inflammatory cells. The inflammation may be intense enough to thicken the conjunctiva, obscure the normal pattern of conjunctival blood vessels, and even obscure the follicles.

3.3 Entropion

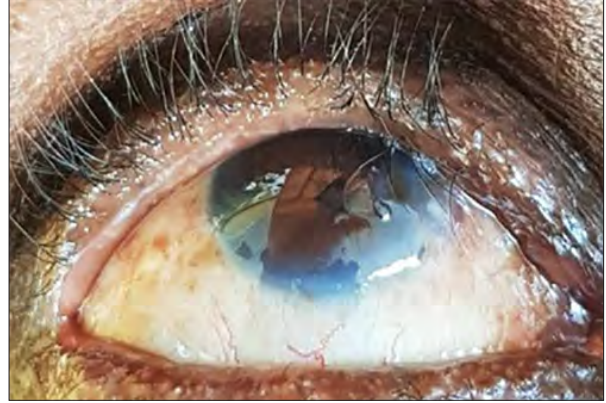
Chronic inflammation due to repeated infection with *C. trachomatis* leads to scarring of the tarsal plate and conjunctiva of the inside of the eyelid. This can turn the eyelid margin inwards, causing ENTROPION. In a normal eyelid, the entire eyelid margin is visible (Fig. 2a, green line). When entropion is present, part or all of the eyelid margin is not visible (Fig 2b; the yellow line shows the only portion of the eyelid margin visible in an eyelid with entropion).

Fig. 2. Normal eyelid margin and eyelid margin with entropion

Fig. 2a.
Normal eyelid margin
(green line shows the eyelid margin)

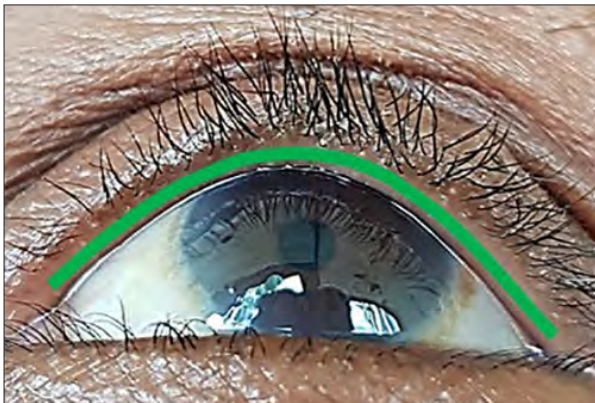
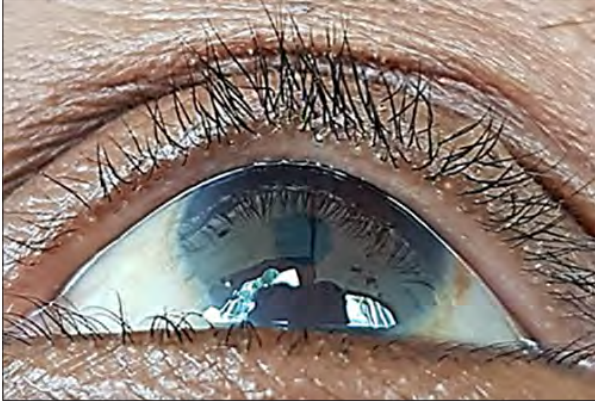
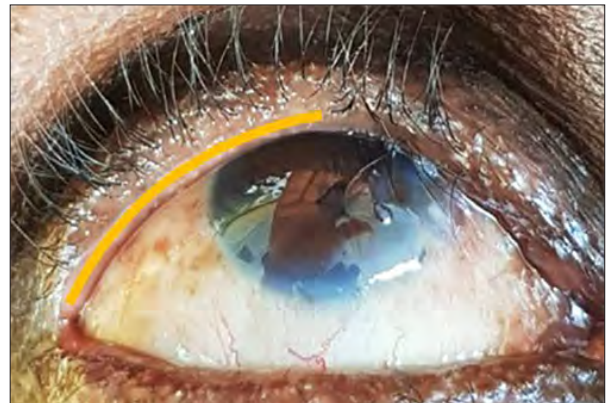Fig. 2b.
Eyelid margin with entropion
(yellow line shows the only portion
of the eyelid margin visible in
this eyelid with entropion)



3.4 **Trichomatous trichiasis (TT)**

When scarring from trachoma causes one or more eyelashes from the upper eyelid to come into contact with the eyeball, the condition is called TRACHOMATOUS TRICHIASIS, “TT” (Figs 1c and 1d). TT is defined as the condition where at least one eyelash from the upper eyelid touches the eyeball (Fig. 1c, arrow), or where there is evidence of recent epilation of in-turned eyelashes from the upper eyelid. This definition excludes trichiasis that affects only the lower eyelid.

TT and entropion are not the same thing. Not all eyes with TT also have entropion. The purpose of TT surgery is to correct the trichiasis and entropion by rotating the eyelid margin outward, directing the eyelashes away from the eyeball.

There may be other causes of trichiasis and of entropion besides trachoma, such as blepharitis, Stevens–Johnson syndrome, burns, trauma, tumours, herpes zoster, metaplastic eyelashes, and ocular cicatricial pemphigoid. Management of trichiasis or entropion caused by processes other than trachoma is not covered in this manual.

3.5 **Corneal scarring**

When the eyelid is affected by trichomatous scarring, with distorted glands and abnormal secretions as well as TT, rubbing of the eyelashes on the cornea disturbs the normal corneal surface and causes scarring (CORNEAL OPACITY). This leads to gradual loss of vision and eventually to blindness. TT surgery can restore a modest amount of vision but cannot help reverse severe vision loss. In these cases, TT surgery prevents pain and further vision loss.

4. History of and examination for upper eyelid trichiasis and entropion

LEARNING OBJECTIVE: TO BE ABLE TO DIAGNOSE TT WITH QUESTIONS ABOUT EYE PROBLEMS AND TO DEMONSTRATE THE ELEMENTS OF AN EXAMINATION

4.1 Questions to help identify someone who may have TT

- (a) Ask the patient if they have a problem with their eyes.
- (b) Ask the patient if they (or another person helps) pull out their eyelashes or EPILATE.
- (c) Ask the patient if they have PAIN in their eyes.
- (d) Ask the patient if they have TEARING or watery eyes.
- (e) Ask the patient if they have a problem seeing in bright sunlight.
- (f) If there is a word in the local language for trichiasis, ask the patient if they have trichiasis.

4.2 Examination of the eyelid

- (a) Examine the patient indoors or in the shade because bright sunlight produces shadows that make the edge of the eyelid difficult to see. Also, patients may be very sensitive to sunlight.
- (b) Ask the patient to look straight ahead with his or her eyes open in the normal way.
- (c) Start with the right upper eyelid. Use a torch and shine it up on the eyelid margin FROM BELOW. 2.5 × magnifying loupes should be used to clearly see TT.
- (d) Locate the eyelid margin and eyelashes and look from different angles (below, temporal and nasal sides). Determine if any eyelashes from the upper eyelid touch the eyeball, or if there is evidence of recent removal of in-turned eyelashes from the upper eyelid.
- (e) Ask the patient to look to the right, then to the left, and watch to see if any eyelashes touch the eyeball.
- (f) Examine for presence or absence of entropion while the patient is looking up by determining visibility of the eyelid margin (Fig. 2). When entropion is present, part or all of the eyelid margin is not visible.
- (g) Use the thumb of your left hand to exert mild pressure on the patient's right upper eyelid, so that the eyelid lifts slightly, enabling you to better examine the eyelid margin and position of the eyelashes. The number of eyelashes touching the eye and the number of eyelashes touching the cornea should be noted.

4.3 Examination of the cornea for opacity

Look directly at the cornea and see if a white or hazy area is present, especially one that covers part of the pupil. Opacity within the cornea should be distinguished from a growth over the cornea (pterygium).

4.4 Examination for defective eyelid closure

If the eyelid does not close properly, either because of disease or previous surgery, a more complicated operation will be needed. Defective eyelid closure is present if the eyelids do not meet completely when the eyes are gently closed, as if going to sleep. The white of the eye will still be seen between the eyelids. The way to examine for defective closure is to ask the patient to close both eyes gently, and then shine the torch from below to look for exposure of the eye (a part of the eye not covered by the eyelids). THESE PATIENTS NEED REFERRAL TO AN OPHTHALMOLOGIST, whether or not they have TT.

PRACTICE: TRAINEES WILL PRACTICE ON EACH OTHER, TAKING A HISTORY AND DOING THE EXAMINATION FOLLOWING THE DETAILED PROTOCOL ABOVE.

5. Indications for eyelid surgery

LEARNING OBJECTIVE: TO BE ABLE TO DESCRIBE WHICH TT CASES ARE ELIGIBLE FOR SURGERY

All patients with TT plus entropion should be offered TT surgery. If the patient is not complaining and has only one or two eyelashes, either nasally or temporally, rubbing on the conjunctiva (not the cornea), then other approaches, including high-quality epilation, can be offered. If the patient does not desire TT surgery, even after proper counselling, they should be offered high-quality epilation and must be instructed to return if the pain gets worse, or if vision begins to worsen.

5.1 Definite indications for TT surgery

TT surgery in the community is indicated when:

- (a) One or more eyelashes from the upper eyelid turn in and touch the cornea when the patient looks straight ahead, plus evidence of entropion;
- (b) There is evidence of corneal damage from TT; or
- (c) The patient has severe discomfort from TT.

5.2 Contraindications to performing TT surgery in the community

The cases below require management in a different environment by an appropriately trained surgeon.

- (a) Defective eyelid closure or the presence of TT after previous TT surgery
- (b) TT in children (surgery should be done in hospital, possibly with a general anaesthetic)
- (c) TT in a patient with poor general health (see Section 6)
- (d) Trichiasis of the lower eyelid only, which will require more detailed assessment

PRACTICE: THE TRAINER WILL PRESENT A SERIES OF CASES TO WHICH THE TRAINEE MUST RESPOND CORRECTLY AS TO WHETHER THE PATIENT SHOULD BE OFFERED SURGERY OR WHETHER OTHER OPTIONS SHOULD BE DISCUSSED.

6. Fitness of patients for TT surgery

LEARNING OBJECTIVE: TO BE ABLE TO ASSESS THE FITNESS OF PATIENTS FOR TT SURGERY

The procedure must cause only minimal risk to the general health of the patient.

6.1 Questions about general fitness

- (a) Does the patient have difficulty in cooperating and following instructions due to hearing or cognitive loss? Be certain this is not simply an issue of differences in dialect or language between the patient and surgeon.
- (b) Ask the patient if he or she has SHORTNESS OF BREATH that results in difficulty lying flat for 30 minutes. This symptom may indicate evidence of HEART FAILURE.
- (c) Ask the patient if he or she knows if they have DIABETES (“sugar”), or HIGH BLOOD PRESSURE, and if they are taking medication for these conditions.
- (d) Very rarely, a person may be ALLERGIC to local anaesthetic, or have a BLEEDING DISORDER. Ask the patient if he or she has previously experienced any problems with injections of local anaesthetic for surgery, or with excessive bleeding if cut (this does not relate to menstrual bleeding).

If the patient has HEART FAILURE, known but untreated DIABETES or untreated HYPERTENSION, ALLERGY TO LOCAL ANAESTHETIC, OR A BLEEDING ABNORMALITY, TT SURGERY SHOULD NOT BE DONE IN A COMMUNITY CLINIC. Refer the patient to a doctor for management of the medical condition first, and to consider whether TT surgery can be performed under medical supervision in a hospital.

If the patient seems to be unable to follow instructions, the patient may not be able to give a true informed consent and may not be able to cooperate during surgery. Engage the patient in sufficient discussion to decide if the procedure can go forward.

PRACTICE: THE TRAINEES WILL PRACTICE WITH EACH OTHER, ASKING QUESTIONS TO IDENTIFY CONDITIONS SUGGESTING THAT THE PATIENT SHOULD NOT HAVE SURGERY AND SHOULD BE REFERRED, AND DESCRIBING THE APPROPRIATE ACTION INDICATED BASED ON THE ANSWER GIVEN.

7. Facilities and surgical materials

LEARNING OBJECTIVE: TO BE ABLE TO LIST KEY INSTRUMENTS AND CONSUMABLES REQUIRED FOR TT SURGERY

7.1 Facilities required

The operating room should be:

- (a) CLEAN with covered windows to exclude dust and flies
- (b) SUFFICIENTLY VENTILATED
- (c) WELL-LIT using a focused light powered by reliable electricity or a battery. Surgery may be performed by daylight, if necessary, but this is less satisfactory.
- (d) LARGE ENOUGH to allow the patient to lie down and the surgeon to work
- (e) CLOSE TO WHERE PATIENTS LIVE, where possible, to avoid the expense and inconvenience of travel, and to retain a familiar environment

7.2 Surgical materials

(a) Instruments required:

No.	Item
1	Autoclave or pressure cooker
1	Large metal bowl or plastic bucket, 4.5 L 260 mm × 125 mm
1	Kidney dish, 0.5 L 250 mm × 36 mm
1	Stainless steel galley pot, 100 mL
1	Scalpel handle No. 3 for a No. 15 blade
1	Needle holder (with or without catch), Silcox or Casteroviejo
1	Toothed forceps 1 × 2 (0.5 mm teeth and 100 mm length) with tying platform
1	Tissue forceps (serrated)
1	Scissors, straight with blunt ends
1	Scissors, curved with blunt ends
2	Small haemostat forceps (“mosquitos”)
1	TT or Waddell clamp (different sizes) or Trabut plate
1	Stainless steel sterilization box (large)
1	Headband operating loupes with 2.5 × magnification

(b) Recommended consumables and supplies:

1% tetracycline eye ointment or topical azithromycin

Oral azithromycin, 1 g dose (if available)

Topical anaesthetic

2% lidocaine or lignocaine local anaesthetic (preferably WITH 1:100 000 epinephrine)

Sterile water or normal saline

10% povidone iodine skin preparation, aqueous solution without alcohol or detergents

70% alcohol

21G disposable needles

5 mL disposable syringes

No. 15 scalpel blades

Sterile surgical gloves (appropriate size for the surgeon)

Gauze/patches

Zinc strapping 2.5 cm × 5 m

A sterile drape, approximately 1 m × 1 m in size, with a central hole approximately 6 cm in diameter made of linen or sterilized single-use drape material.

Mask and cap (and gown if available) for surgeon

Sutures: 4/0 black silk or 5/0 polygalactin with 19 mm, 3/8th circle reverse-cutting needle or spatulated needle, 45 cm length

Sharps (safe) disposal box

PRACTICE: THE TRAINER SHOULD ASK THE TRAINEE TO CREATE THE LISTS OF REQUIRED INSTRUMENTS AND SUPPLIES AND DESCRIBE WHERE THEY WILL OBTAIN THE ITEMS.

8. Sterilization

LEARNING OBJECTIVE: TO UNDERSTAND THE PRINCIPLES OF STERILITY, BE ABLE TO STERILIZE EQUIPMENT, AND BE ABLE TO PREPARE FOR STERILE SURGERY

TT surgery involves creating a wound and thus exposes the patient to the risk of infection. Transmission of infection between surgeon and patient or between subsequent patients is possible if sterile practices are not followed. Trainees must understand the principles of sterility and sterile technique, which is the way sterile materials are handled in order to keep them free of contamination by live organisms.

8.1 Principles of sterility

- (a) ALL MATERIALS used as a part of the sterile field for an operation MUST BE STERILE. For example, the drapes or towels that surround a patient's face must be sterilized, not just washed.
- (b) Surgical instruments may be sterilized the night before or immediately preceding the operation and taken directly from the sterilizer to the sterile operative field.
- (c) Once an item is removed from a sterile wrapper or sterilizer, it must be used, discarded, or re-sterilized. Items should be considered unsterile if there is any doubt about their sterility.
- (d) If there is any doubt about the timing of a sterilization process, the supplies are considered unsterile and must be re-sterilized.
- (e) If an unsterile person or item touches a sterile object, the object is considered CONTAMINATED AND NOT STERILE. If a "sterile" surgeon touches an unsterile object, the surgeon is now considered contaminated. For example, if the room is warm and the surgeon wipes his or her brow with a sterile glove, that glove must be removed and replaced with a new sterile glove.
- (f) All surgical team members should wash their hands using techniques described below before starting surgery and change gloves after the care of each patient.

Because of the risk of infection transmission, particularly of HIV, it is essential that instruments be sterilized before each operation. **SURGERY MUST NOT BE PERFORMED IF THE INSTRUMENTS CANNOT BE PREPARED IN ONE OF THE WAYS DESCRIBED BELOW.**

Needles, syringes, blades and sutures are intended for single-patient use. They should be discarded appropriately and not be re-used for multiple patients.

8.2 Definition of sterility

Sterilization is defined as the destruction of all viruses, bacteria and spores.

(a) Sterilization by steam

Steam sterilization is performed under pressure for at least 15 minutes after the load reaches a temperature of 121 °C (250 °F), at a pressure of 1 atmosphere above atmospheric pressure (101 kPa, 15 lb/sq.in.) and after water vapour saturation.

(b) Sterilization by dry heat

Sterilization in an electric or gas oven is achieved after 2 hours at 170 °C (340 °F), allowing additional time prior to this for the load to equilibrate at that temperature.

PRACTICE: THE TRAINER SHOULD PROVIDE A SERIES OF ORAL EXAMPLES WHERE STERILITY MIGHT BE LOST AND THE TRAINEE MUST RECOGNIZE THE CONTAMINATION IN SUCH CASES.

THE TRAINEE MUST USE A PRESSURE COOKER OR AUTOCLAVE WITH A SET OF INSTRUMENTS, AND DEMONSTRATE HOW TO LOAD, SET, AND PROPERLY UNLOAD THE INSTRUMENTS TO MAINTAIN STERILITY.

9. Preparation

LEARNING OBJECTIVES:

- (a) TO BE ABLE TO EXPLAIN IN SIMPLE TERMS TO THE PATIENT WHAT TRICHIASIS IS, HOW THE OPERATION IS PERFORMED, AND WHAT THE PATIENT SHOULD EXPECT AFTER SURGERY.
- (b) TO BE ABLE TO SCRUB HANDS, PUT ON GLOVES WHILE MAINTAINING STERILITY, AND CREATE A STERILE FIELD FOR THE SURGERY.

9.1 Preoperative patient preparation

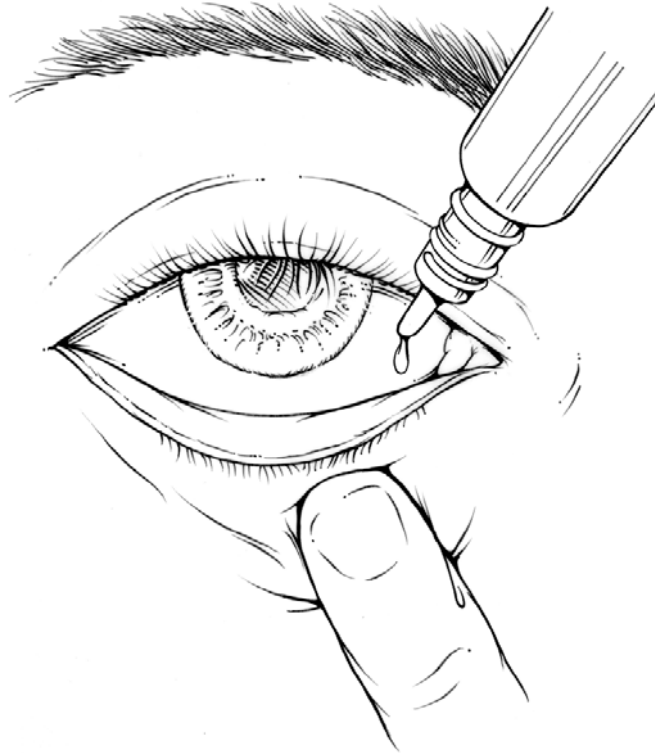
- (a) EXPLAIN to the patient what their condition is and how it will lead to vision loss.
- (b) EXPLAIN what the operation is for and what the patient can expect during the operation and afterwards.
- (c) ASK him or her to sign, or to mark appropriately, a consent form.
- (d) Ensure the patient's face is CLEAN and free of eye make-up.
- (e) Ask the patient to LIE DOWN on the operating table.
- (f) EXPLAIN further that:
 - (i) He or she should lie quietly and still during the procedure.
 - (ii) He or she will receive numbing drops that might sting at first.
 - (iii) He or she might feel the sting of the injection, but this will not be for long.
 - (iv) He or she should not feel pain during the operation and, if there is pain, he or she should tell the surgeon.
 - (v) Clean towels will cover the face and chest, so the operation is clean.
 - (vi) He or she must not move the towels, try to touch the eye, or touch the surgeon, so the operation remains clean.

PRACTICE: THE TRAINEES SHOULD PRACTICE THE EXPLANATIONS WITH EACH OTHER. THE TRAINEES SHOULD PRETEND TO BE THE PATIENT AND ASK QUESTIONS, AND THEN PRETEND TO BE THE SURGEON EXPLAINING THE ANSWERS.

9.2 Applying the local anaesthetic drops

Ask the patient to look up. Pull down the lower eyelid and put in two drops of topical anaesthetic (Fig.3). Ask the patient to close the eye gently for a minute or two. The dropper should not touch the eye, eyelid, or your finger.

Fig. 3. Applying a local anaesthetic drop



9.3 Sterile preparation of the surgeon's (and assistant's) hands and the patient's skin

- (a) Put on the surgical mask, cap and magnifying loupes and adjust them before scrubbing hands.
- (b) SCRUB THE HANDS (both the surgeon's and the assistant's hands, if an assistant is present) with soap and water for five minutes, then WASH with 10% povidone iodine (or an alternative skin antiseptic solution) and RINSE with sterile water. Hands should be dried using a sterile towel. Once hands are scrubbed, they must not touch anything other than the sterile drying towel until covered with sterile gloves.
- (c) PUT ON STERILE GLOVES using proper technique without contaminating them (both surgeon and assistant). Because of the risk of infection, GLOVES MUST BE WORN. The trainer should demonstrate how to put gloves on without contaminating them.
- (d) Use a STERILE DRAPE to make a sterile field on a table.
- (e) Remove the instruments from the autoclave or pressure cooker using sterile gloves or sterile forceps and place the sterile instruments in the sterile kidney dish on the sterile drape. These instruments are ready for use.
- (f) CLEAN THE PATIENT'S FACE. A gauze soaked in 10% povidone iodine solution is used to thoroughly clean the patient's closed eyelids and surrounding area. The technique of cleaning in a circular pattern, starting at the eyelids and moving outwards towards the face should be used. The patient's face should be touched only with the gauze. If the surgeon's glove touches the face before cleaning, the glove becomes contaminated. Avoid getting the povidone iodine in the patient's eyes and rinse with sterile water if povidone iodine gets into the eyes.

PRACTICE: THE TRAINEE MUST DEMONSTRATE WASHING HANDS APPROPRIATELY, PUTTING ON GLOVES IN A STERILE FASHION, AND CREATING A STERILE FIELD FOR THE SURGERY.

10. Injecting local anaesthetic

LEARNING OBJECTIVE: TO BE ABLE TO ANESTHETIZE THE UPPER EYELID WITH MINIMAL DISCOMFORT FOR THE PATIENT

The anaesthetic usually used is 2% LIDOCAINE WITH 1:100 000 EPINEPHRINE. Check the label to confirm the type of anaesthetic and the expiration date just before use.

10.1 Keeping the lidocaine in the bottle sterile

- (a) CLEAN the rubber stopper of the bottle with a sterile swab soaked in antiseptic, e.g. 10% povidone iodine, before perforating with the needle.
- (b) USE A NEW STERILE NEEDLE AND SYRINGE to draw up lidocaine. If you need to draw up more, even for the same patient, use another new needle and syringe.
- (c) If separate ampoules are used, open a fresh ampoule for each patient.

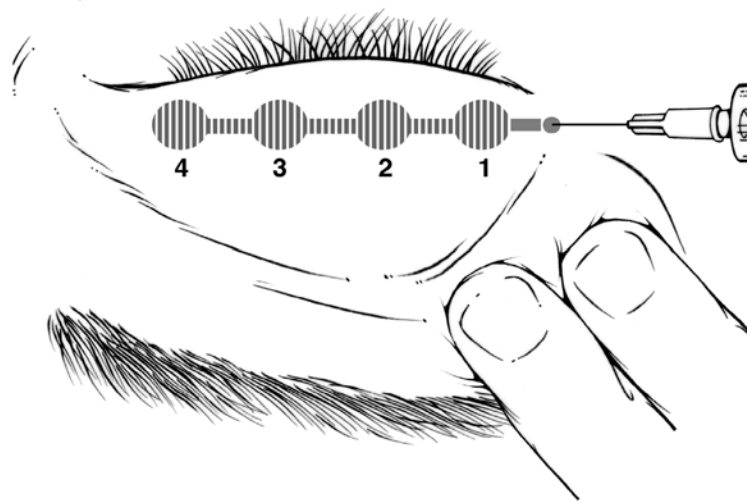
10.2 The injection

- (a) Draw up 3 mL if operating on one eye. If operating on both eyes, draw up 5 mL.
- (b) Inject the lidocaine into the upper eyelid from the temporal side.
 - (i) Stand beside the patient. If only one eyelid is to have surgery, CONFIRM which eyelid requires surgery and on which side the patient has consented to have surgery.
 - (ii) Ask the patient to gently close their eyes.
 - (iii) Draw the upper eyelid laterally with your fingers.
 - (iv) Insert the needle into the muscle beneath the skin in front of the tarsal plate, about 3 mm above the eyelid edge, parallel to the eyelid margin (Fig. 4).
 - (v) Begin to SLOWLY inject the lidocaine. Slowly slide the needle through the tissues as the lidocaine is injected AHEAD OF THE NEEDLE. Proceed across the eyelid following the curve of the eyelid, 3 mm above the eyelid margin, injecting a total of 2 mL of local anaesthetic. The needle should be IN FRONT OF THE TARSAL PLATE and should slide easily as you advance and inject the lidocaine.
 - (vi) Massage the lidocaine into the eyelid for 1 minute with gentle finger pressure. To reduce discomfort for the patient, do not press on the eyeball but pull the eyelid slightly upwards and massage against the orbital rim.
 - (vii) Slow injection is less painful for the patient.
 - (viii) Wait a total of 3 minutes until the lidocaine has taken effect. Test by gently pinching the skin of the eyelid with forceps. The patient should feel no pain, although he or she may feel movement.

- (viii) If pain is felt, inject another 1 mL of lidocaine, for a total of 3 mL. Usually 3 mL is sufficient.
- (ix) During the surgery, if the patient begins to feel pain, additional lidocaine can be injected, but never inject more than 5 mL in any one eyelid in one operation.

DO NOT INJECT MORE THAN A TOTAL OF 5 mL PER EYELID PER OPERATION.
NEVER INJECT INTO THE EYE.

Fig. 4. Injecting local anaesthetic*



*This drawing is of the right eye,
from the perspective of the surgeon
at the head of the bed.

11. Surgical procedure

LEARNING OBJECTIVES:

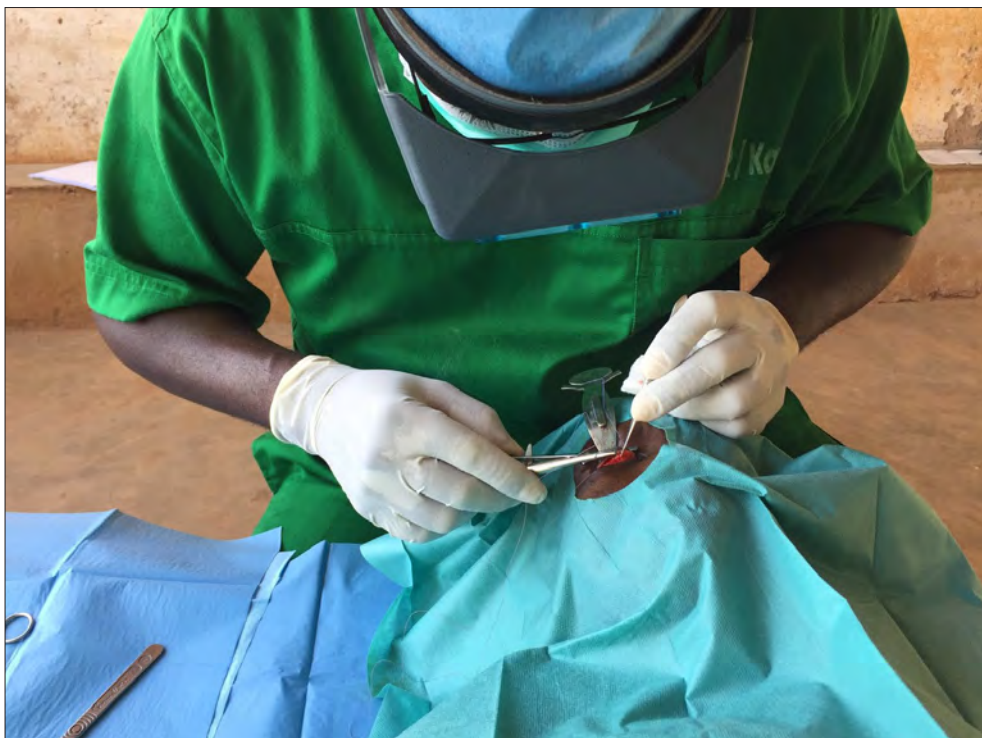- (a) TO BE ABLE TO PERFORM SUCCESSFUL BILAMELLAR TARSAL ROTATION AND/OR POSTERIOR LAMELLAR TARSAL ROTATION (MODIFIED TRABUT) PROCEDURES TO CORRECT TT
- (b) TO BE ABLE TO DESCRIBE POSSIBLE SURGICAL DIFFICULTIES THAT CAN ARISE DURING SURGERY AND IMMEDIATELY AFTERWARDS, AND DESCRIBE WHAT TO DO

11.1 Bilamellar tarsal rotation procedure

In the bilamellar tarsal rotation operation, a full thickness incision is made through the upper eyelid parallel to the eyelid margin. The portion of the eyelid containing the eyelashes is rotated outwards so that the eyelashes are no longer in contact with the cornea, and this position is secured with sutures.

The operation is performed with the surgeon seated at the head of the patient facing the patient's feet (Fig.5). A sterile drape is placed over the face, with the eye visible through the central opening. The surgeon's wrists can be steadied on the patient's forehead during surgery.

Fig. 5. Position of surgeon and patient.
The posterior lamellar tarsal rotation (modified Trabut) procedure is shown; the position of surgeon and patient is the same for the bilamellar tarsal rotation procedure.



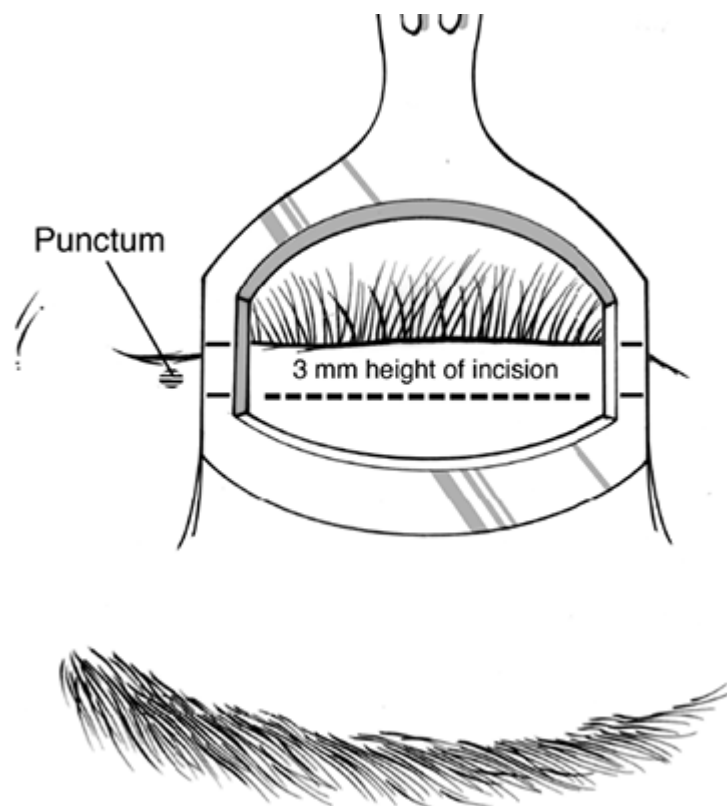
© Amir B. Kello

11.1.1 Stabilizing the eyelid

Either the TT clamp or the Waddell clamp should be used. Use the largest size clamp that fits the eye.

The TT clamp is placed so that the eyelid margin lines up with the groove on the plate. Then the TT clamp is secured (Fig. 6). The Waddell clamp is placed so that the eyelid margin is up against the vertical piece on the clamp, and then the Waddell clamp is secured. The plate between the eyelid and the eye allows a full-thickness incision to be made with either clamp with one pass of the scalpel blade.

Fig. 6. Bilamellar tarsal rotation procedure: eyelid stabilization*

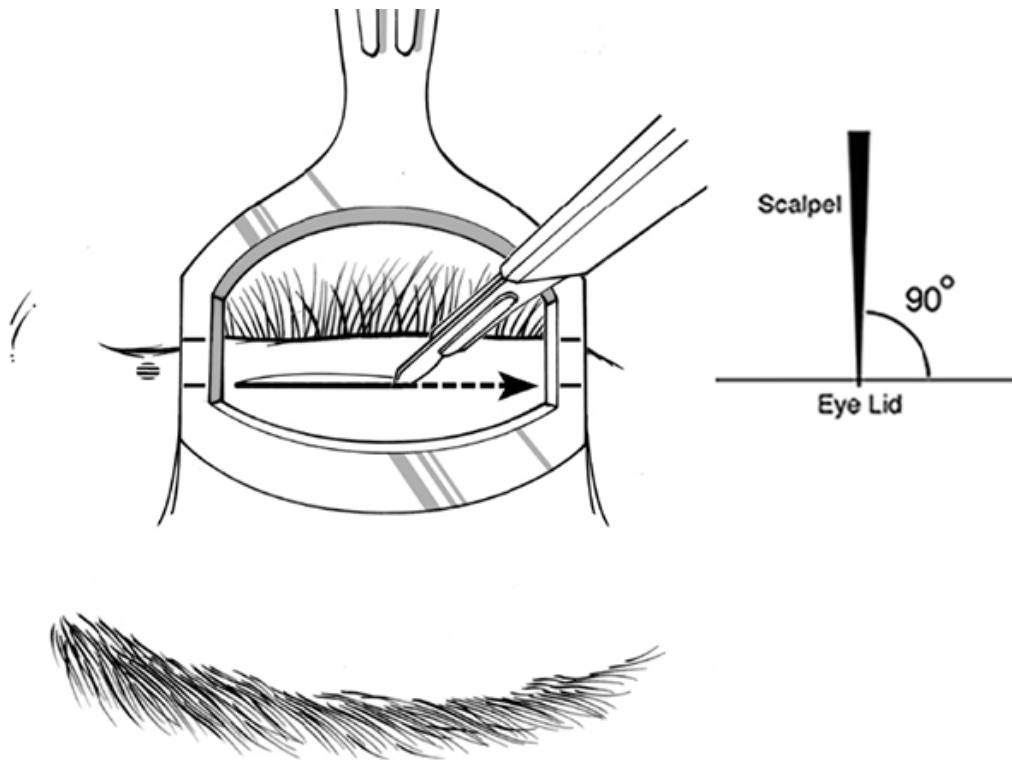


*This and figures 7–18 are of the right eye, from the perspective of the surgeon at the head of the bed. Drawings and descriptions assume that the surgeon is right-handed. Discussion between trainer and trainee will aid translation of these materials for use by left-handed surgeons and for operating on the left eye.

11.1.2 Creating the incision

Incise the skin, muscle and tarsus (Fig.7). The incision is made “full-thickness” through all layers down to the metal plate from one side of the clamp to the other with the scalpel blade held at right angles to the skin.:

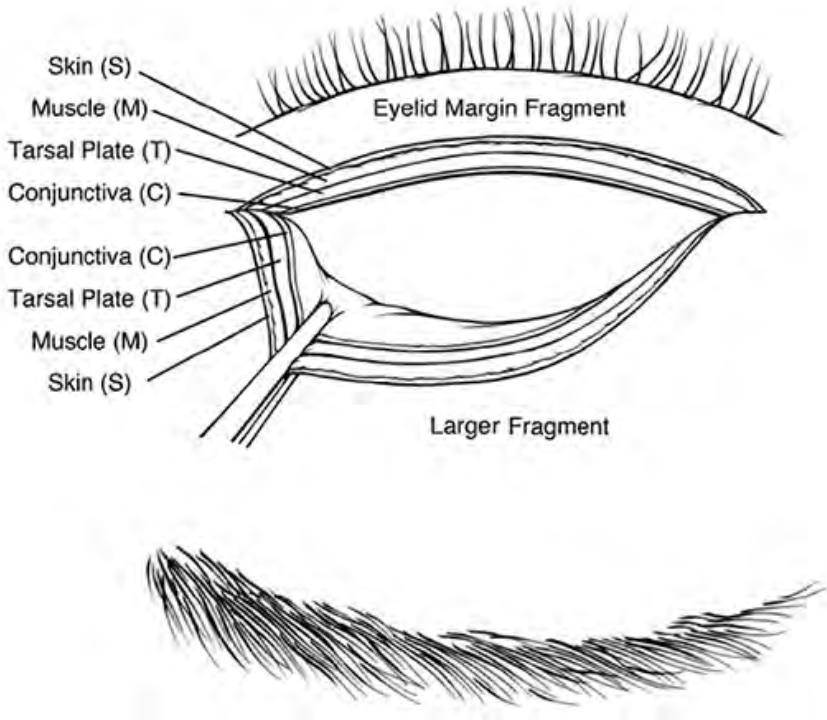
Fig. 7. Bilamellar tarsal rotation procedure: incision



THE EYELID SHOULD NOW BE DIVIDED THROUGH ITS ENTIRE THICKNESS, 3 mm FROM AND PARALLEL TO THE EYELID MARGIN, REMAINING CONNECTED AT BOTH NASAL AND TEMPORAL ENDS. ON AVERAGE, THE INCISION SHOULD BE 22 mm IN LENGTH WHERE POSSIBLE.

We shall refer to the 3 mm eyelid margin portion that contains the eyelashes as the EYELID MARGIN FRAGMENT and the remaining portion as the LARGER FRAGMENT (Fig. 8).

Fig. 8. Bilamellar tarsal rotation procedure: incised eyelid and parts



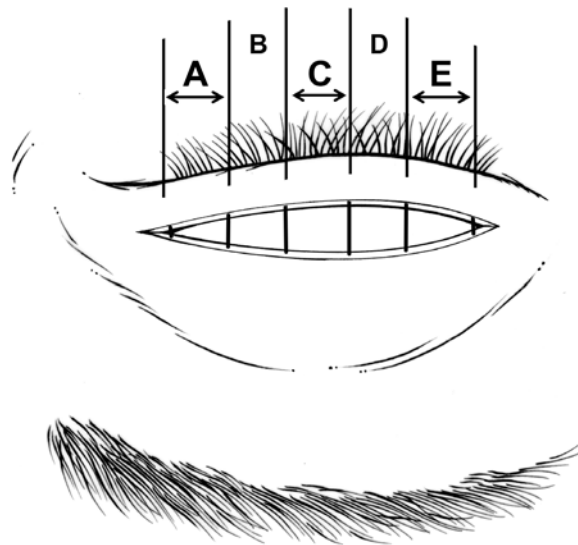
11.1.3 Suturing the eyelid

The purpose of the sutures is to reattach the eyelid margin fragment in an outwardly rotated position, so that the eyelashes no longer rub on the cornea. This is achieved by anchoring the skin and muscle of the eyelid margin fragment near the eyelashes to the tarsus of the larger fragment, thus drawing the eyelid margin outwards and the eyelashes upwards.

4/0 silk is suitable for suturing, and absorbable sutures can also be used. The following description of suturing presumes use of a single armed needle. Note that the clamp is left on for haemostasis during suture placement, although this is not shown in the following figures.

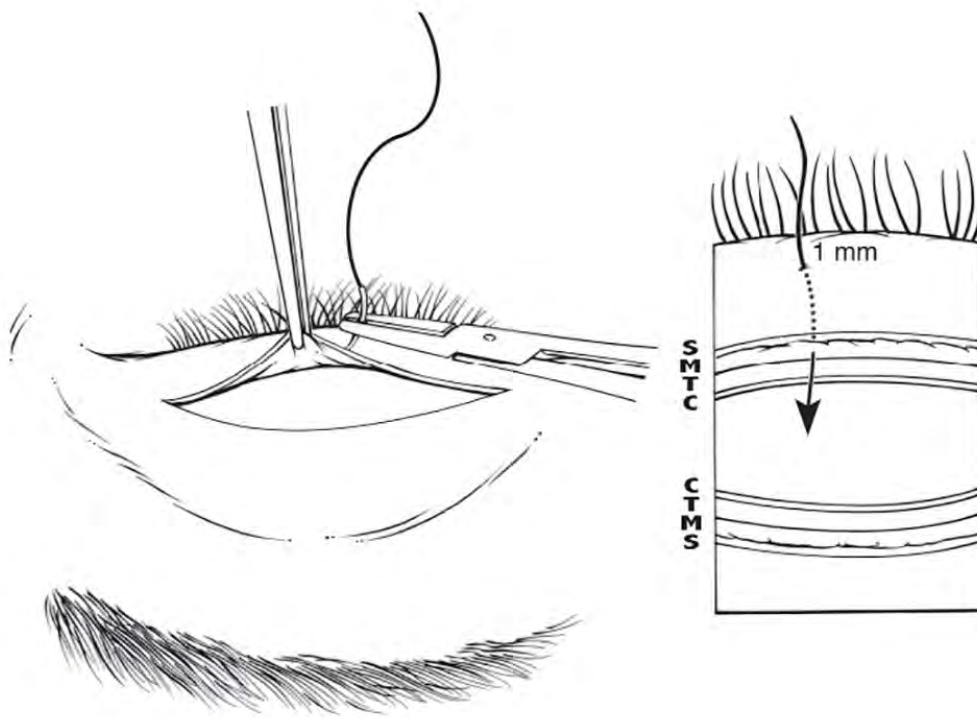
- (a) Placing the centre suture in the eyelid margin fragment :
 - (i) Look down at the SKIN SURFACE of the eyelid margin fragment. Mentally divide the eyelid margin into five sections that will be defined by the placement of three sutures (Fig. 9). Three of those sections (Fig. 9 "A", "C" and "E") will be spaces between two lengths of single sutures, and two (Fig. 9 "B" and "D") will be spaces between two lengths of different, adjacent sutures. The centre suture will be placed first. One suture will be placed on either side of the centre suture and will be spaced equidistant from the centre suture.

Fig. 9. Bilamellar tarsal rotation procedure: spacing of the sutures



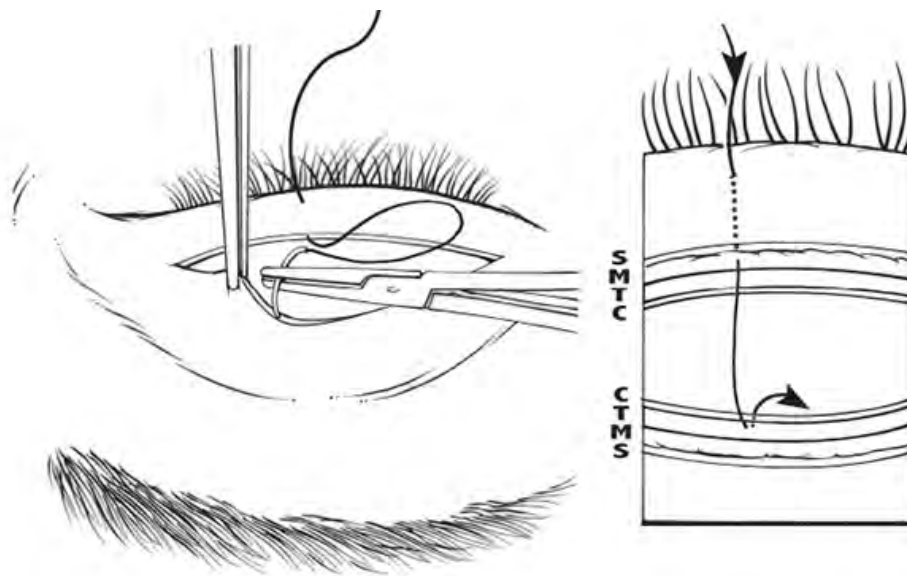
- (ii) Prepare the needle holder: Mount the needle to point TOWARDS you.
- (iii) Grasp the skin of the eyelid margin fragment of the eyelid with toothed forceps at approximately the centre of the incision length, which represents the middle of section C (Fig. 9).
- (iv) Starting just nasal from the centre of the fragment, pass the needle through the skin about 1 mm ABOVE THE EYELASHES to emerge through the cut edge of the muscle layer IN THE FRONT OF (NOT THROUGH) THE TARSAL PLATE. Leave enough of the suture at the end to tie the knot (Fig. 10).

Fig. 10. Bilamellar tarsal rotation procedure: placing the centre suture in the eyelid margin fragment (skin, S; muscle, M; tarsal plate, T; conjunctiva, C)



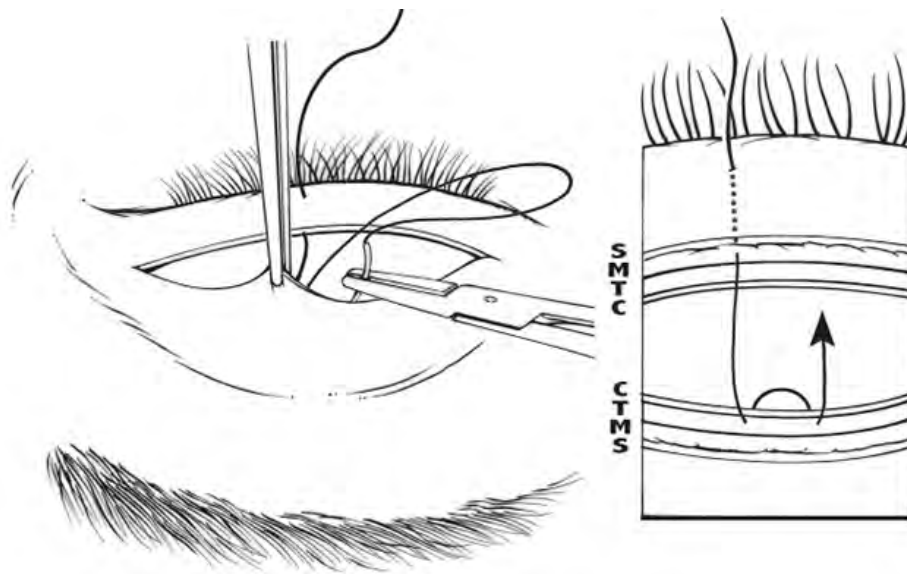
- (d) Placing the centre suture in the larger fragment
- (i) Mount the needle to point **AWAY** from you.
 - (ii) Draw back the skin of the larger fragment of the eyelid with your finger and grasp the cut edge of the tarsal plate with toothed forceps and rotate it slightly towards you. Observe the **PINK CONJUNCTIVA** on the inner surface of the eyelid and the white cut edge of the tarsus. If blood obstructs the view, swab this surface.
 - (iii) Pass the needle and its associated suture into the middle of white cut edge of the tarsal plate (half-thickness). Guide the needle so it emerges through the pink conjunctiva at a point 1 mm from the cut edge of the tarsal conjunctiva. Note the suture entrance into the cut edge of the tarsus should line up straight with the exit of the suture just placed through the skin and muscle of the eyelid margin fragment (Fig. 11).

Fig. 11. Bilamellar tarsal rotation procedure: placing the centre suture in the larger fragment (skin, S; muscle, M; tarsal plate, T; conjunctiva, C)



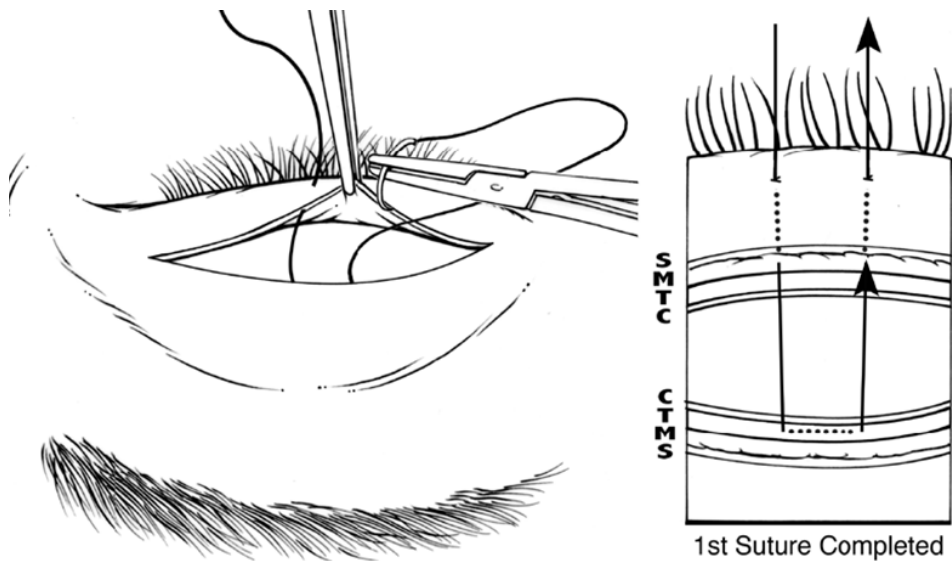
- (iv) Mount the needle to point towards you.
- (v) Grasp again the cut edge of the tarsal plate in the larger fragment with the toothed forceps. Create the suture that will be one-fifth of the incision length, temporal to nasal, of the incision (which should span most of the length of the conjunctiva). Move temporally (on average 5 mm) crossing the midline of the larger fragment. Pass the needle in the opposite direction as the last bite, entering the conjunctiva 1 mm from the cut edge and exiting half thickness through the cut edge of the tarsus.
- (vi) The centre suture should be 1 mm in from the cut edge of the tarsus and symmetrically placed at the centre of the eyelid (Fig.12)

Fig. 12. Bilamellar tarsal rotation procedure: continuing the centre suture (skin, S; muscle, M; tarsal plate, T; conjunctiva, C)



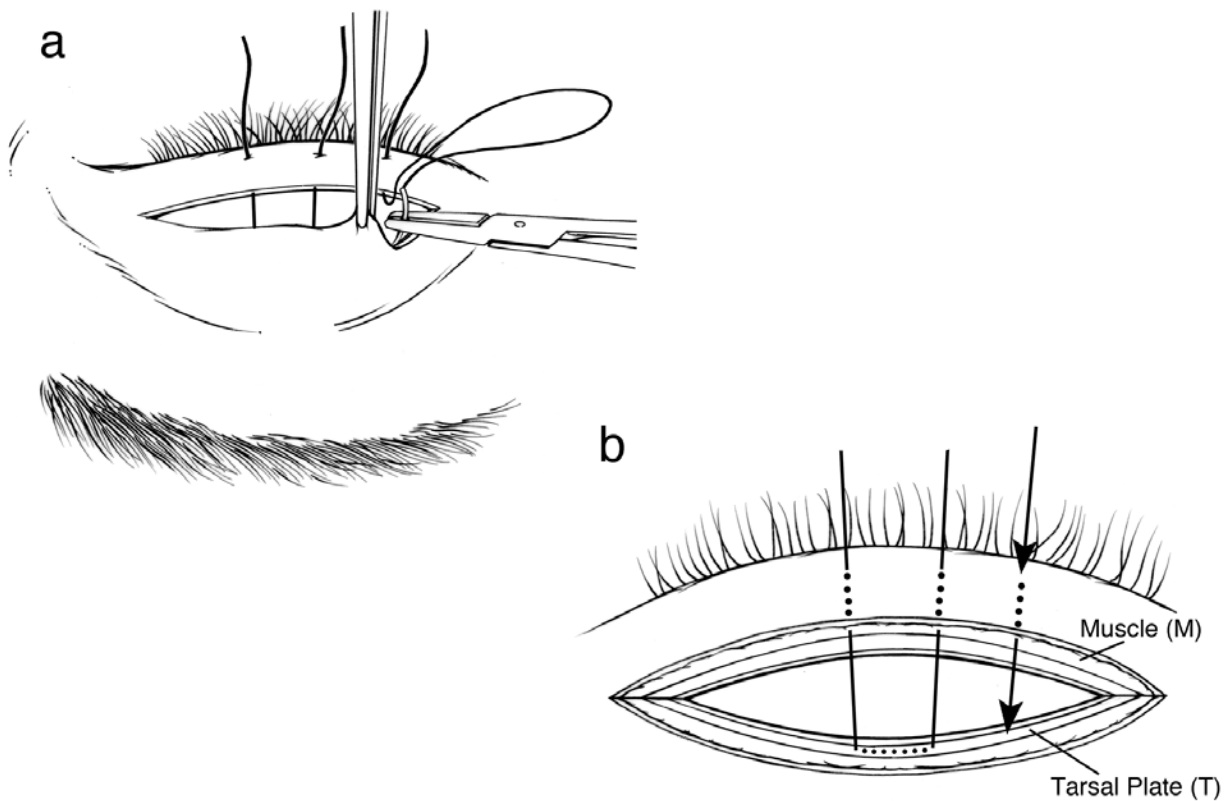
- (c) Returning to the eyelid margin fragment to complete the centre suture
- (i) Mount the needle to point away from you.
 - (ii) Grasp the skin of the eyelid margin fragment.
 - (iii) Pass the needle through the muscle layer in front of the tarsal plate, to emerge through the skin about 1 mm above the eyelashes. The entry point should correspond with the exit site of the suture in the larger fragment. THE TWO ARMS OF THE CENTRE SUTURE MUST BE PARALLEL TO EACH OTHER AND PERPENDICULAR TO THE EYELID MARGIN TO AVOID EYELID CONTOUR ABNORMALITIES (Fig.13).
 - (iv) Leave enough suture to tie a knot and cut the suture. These two ends will be tied later. Now proceed to do one of the side sutures exactly the same way.

Fig. 13. Bilamellar tarsal rotation procedure: completing the centre suture
(skin, S; muscle, M; tarsal plate, T; conjunctiva, C)



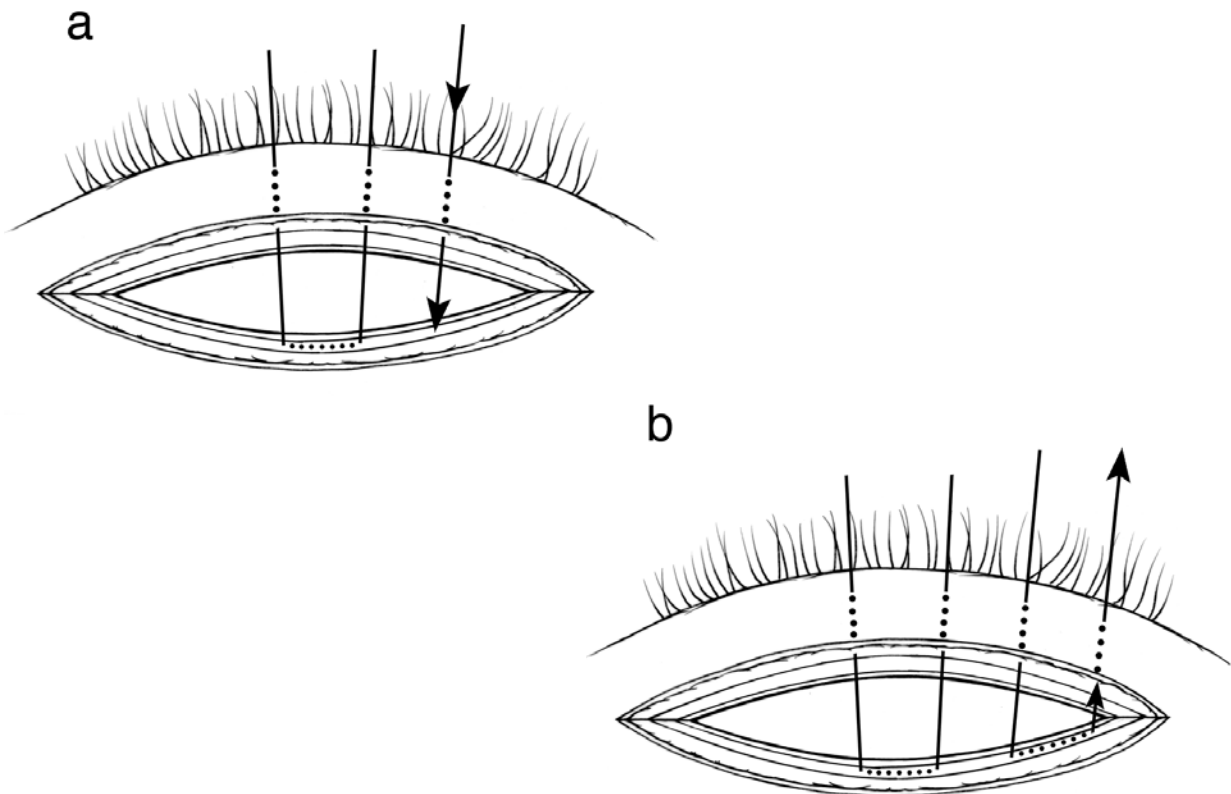
- (d) Placing second (temporal) suture in eyelid margin fragment
 - (i) Mount the needle to point towards you. Continue to hold the skin of the eyelid margin fragment with forceps.
 - (ii) Leave another one-fifth of the eyelid (about 5 mm) between the temporal bite of the centre suture and the first bite of the temporal suture. Pass the needle through the skin about 1 mm ABOVE THE EYELASHES to emerge through the muscle layer IN THE FRONT OF (NOT THROUGH) THE TARSAL PLATE. Leave enough of the suture at the end to tie the knot. Return to the larger fragment.
- (e) Placing second (temporal) suture in the larger fragment
 - (i) Mount the needle to point AWAY from you and proceed again to pass the needle into the cut edge of the tarsal plate, with the needle emerging from the conjunctiva about 1mm in from the cut edge of the tarsus (Fig.14a and b). Again, make sure the suture entrance into the cut edge of the tarsus lines up straight with the exit of the bite in the eyelid margin fragment.

Fig. 14a and b. Bilamellar tarsal rotation procedure: placing the second suture



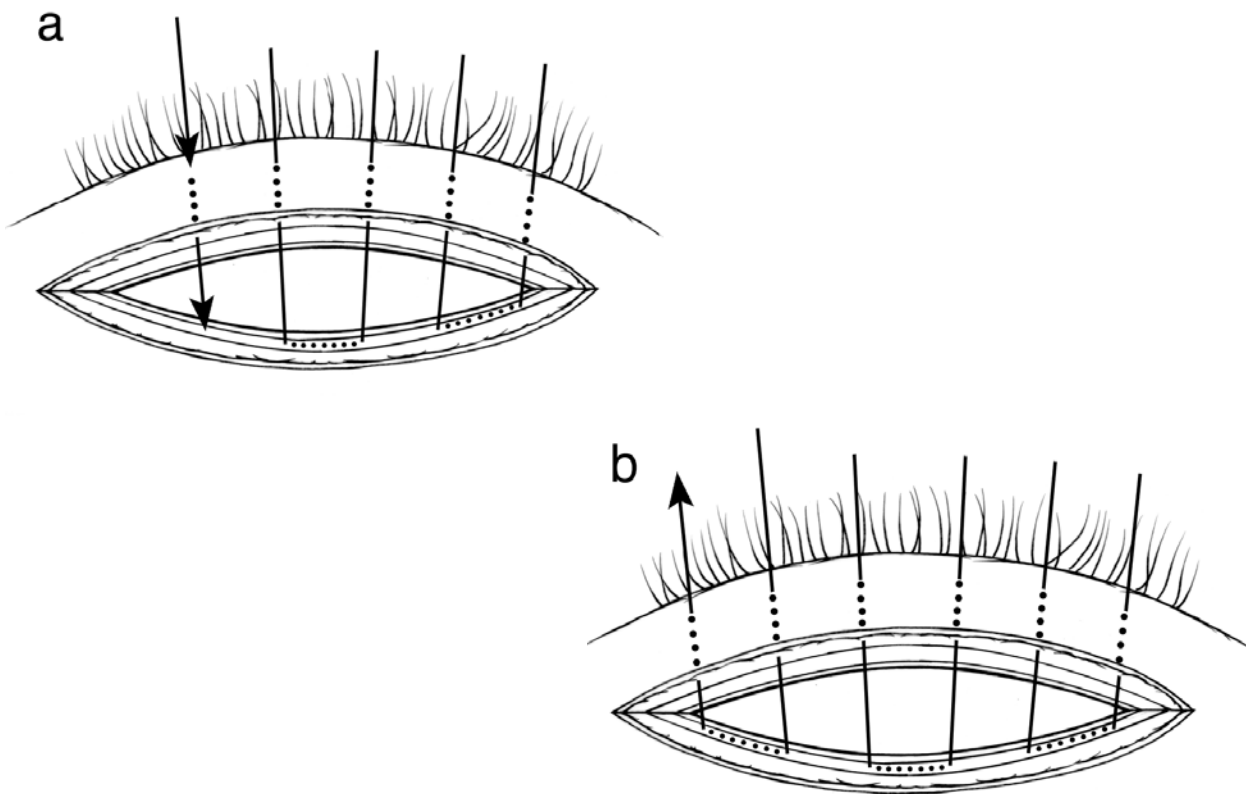
- (ii) Mount the needle to point towards you. Move temporally approximately 5 mm and you should be at the temporal end of the incision. Pass the needle through the conjunctiva 1 mm from the cut edge of the tarsus and exit half thickness through the cut edge of the tarsus. This second suture should be symmetric with the first suture and also 1 mm in from the cut edge of the tarsus.
- (f) Returning to the eyelid margin fragment to complete the second suture.
 - (i) Finish the the second suture by returning to the eyelid margin fragment. Mount the needle to point away from you. Pass the needle through the muscle layer in front of the tarsal plate to emerge through the skin about 1 mm above the eyelashes and at the end of the incision (Fig.14). Leave enough suture to tie a knot later and cut the suture. AGAIN, THE TWO ARMS OF THE TEMPORAL SUTURE MUST BE PARALLEL TO EACH OTHER AND TO THE CENTRE SUTURE, AND PERPENDICULAR TO THE EYELID MARGIN. THIS LINE UP OF SUTURES MUST BE EXACT TO AVOID EYELID CONTOUR ABNORMALITIES.

Fig. 15a and b. Bilamellar tarsal rotation procedure: first two sutures in place



- (g) Create the third (nasal) suture.
- (i) Follow the directions for the second suture, only place the third suture on the nasal side of the centre suture (Fig.16a and b).
 - (ii) Leave another one-fifth of the eyelid (approximately 5 mm) between the nasal bite of the centre suture and the first bite of the nasal suture. Pass the needle through the skin about 1 mm ABOVE THE EYELASHES to emerge through the muscle layer IN FRONT OF (NOT THROUGH) THE TARSAL PLATE. Leave enough of the suture at the end to tie the knot. Return to the larger fragment.
 - (iii) Mount the needle to point AWAY from you and proceed again to pass the needle into the cut edge of the tarsal plate, with the needle emerging from the conjunctiva about 1mm in from the cut edge. Again, make sure the suture entrance into the cut edge of the tarsus lines up straight with the exit of the first bite in the eyelid margin fragment.

Fig. 16a and b. Bilamellar tarsal rotation procedure: placement of third suture

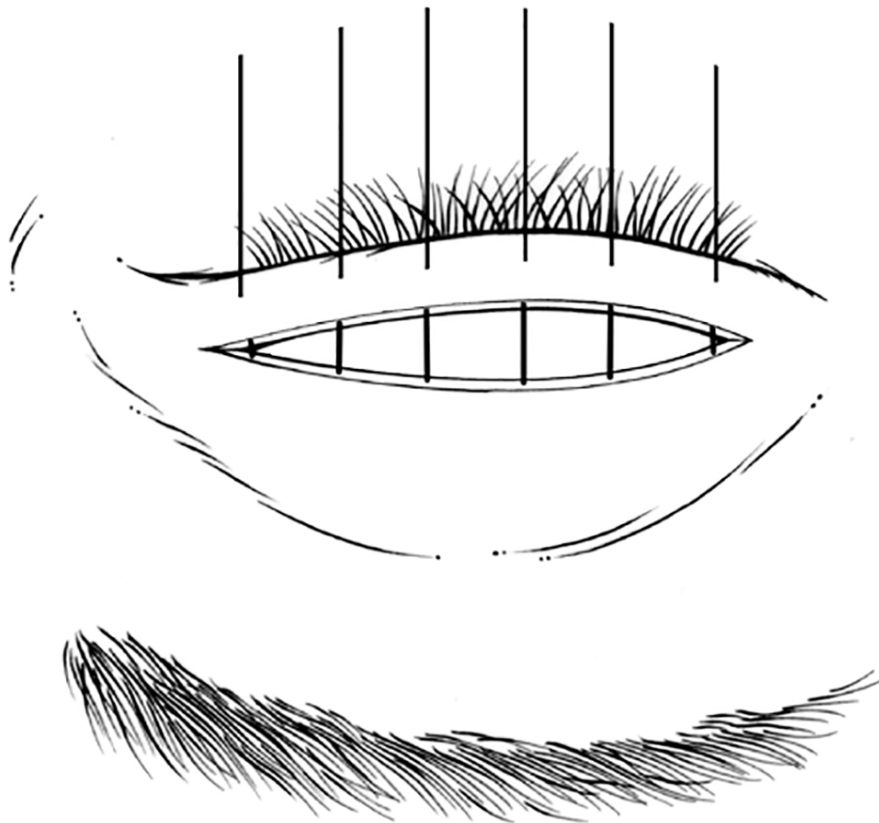


- (iv) Mount the needle to point towards you. Move nasally approximately 5 mm (you should now be at the nasal end of the incision). Create the third suture, which should be symmetrical with the other sutures and also 1 mm in from the cut edge of the tarsus.
- (v) Finish the final suture by returning to the eyelid margin fragment. Mount the needle to point away from you. Pass the needle through the muscle layer in front of the tarsal plate to emerge through the skin about 1 mm above the eyelashes and at the end of the incision.

AGAIN, THE TWO ARMS OF THE NASAL SUTURE MUST BE PARALLEL TO EACH OTHER AND TO THE CENTRE AND TEMPORAL SUTURES, AND PERPENDICULAR TO THE EYELID MARGIN.

- (vi) Leave enough suture to tie a knot at the end of suturing. Cut this final suture. The eyelid and suturing should now look like Fig. 17.

Fig. 17. Bilamellar tarsal rotation procedure: third suture in place



(h) Tying the sutures (Fig. 18)

- (i) **TIE THE CENTRAL SUTURE FIRST** with the first double throws of a surgical knot. Repeat this procedure with the temporal and nasal sutures. Remove the Waddell or TT clamp. Then tighten the double throws **FIRMLY ENOUGH TO PRODUCE A SLIGHT OVERCORRECTION**. Look at the eyelid margin from below (Fig.18) to observe how the eyelid looks before completing the second and third single throws to create a surgical knot.

Fig. 18. Bilamellar tarsal rotation procedure: tying sutures to produce a slight overcorrection

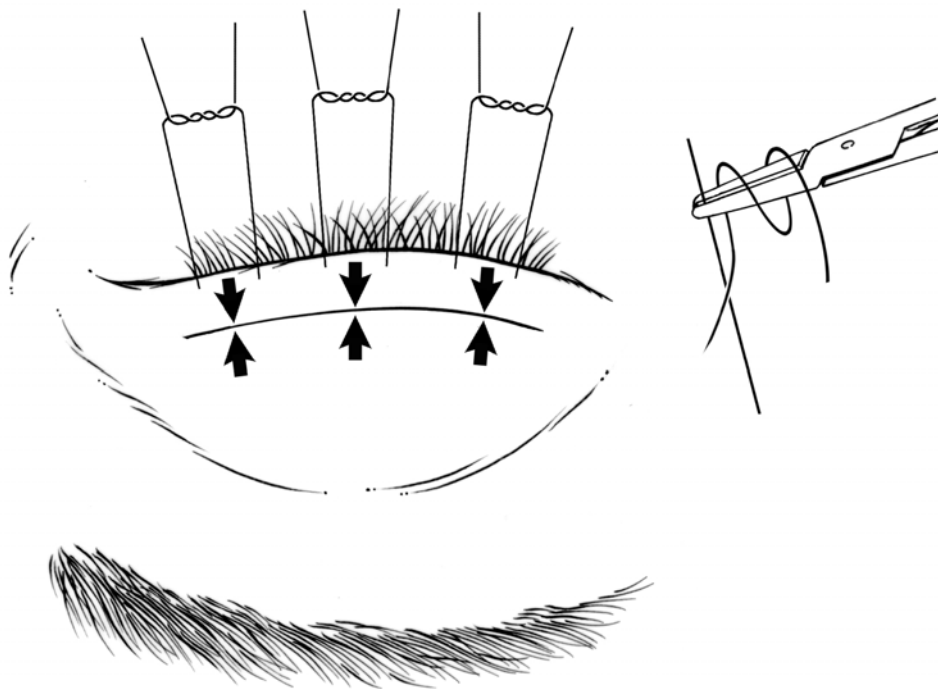
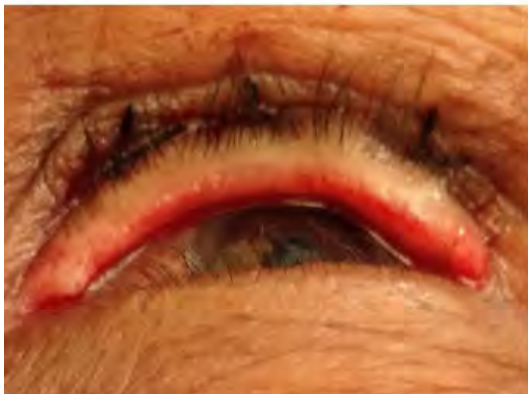
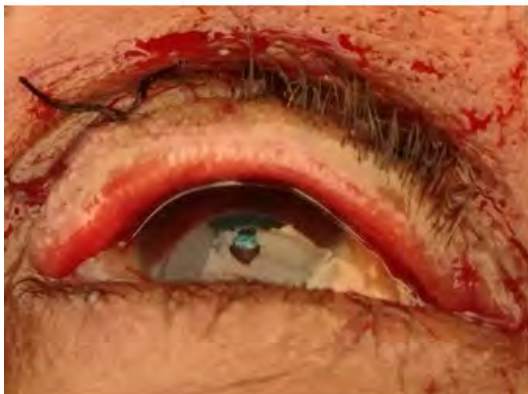
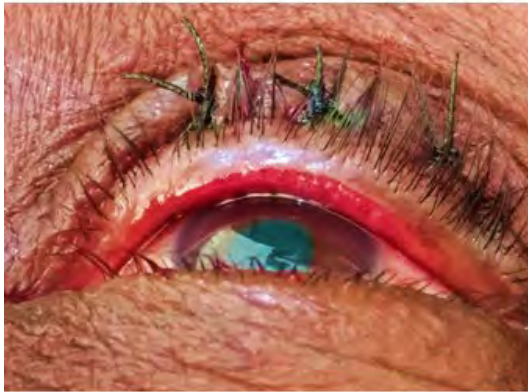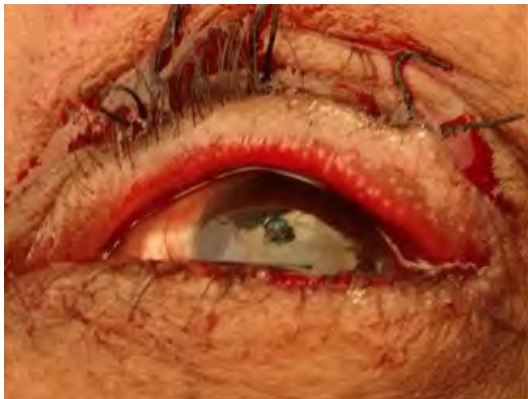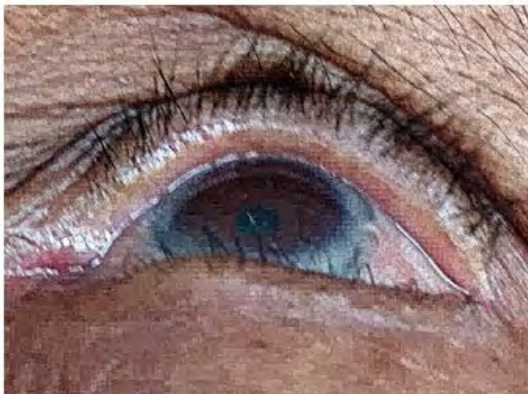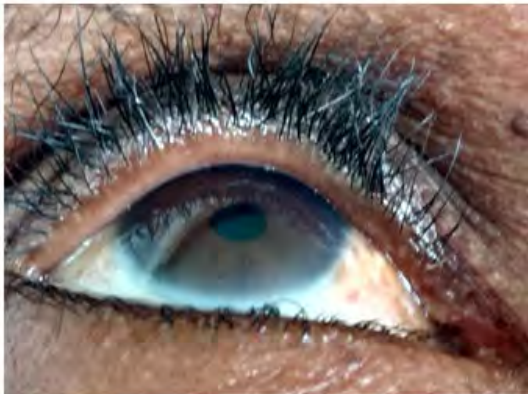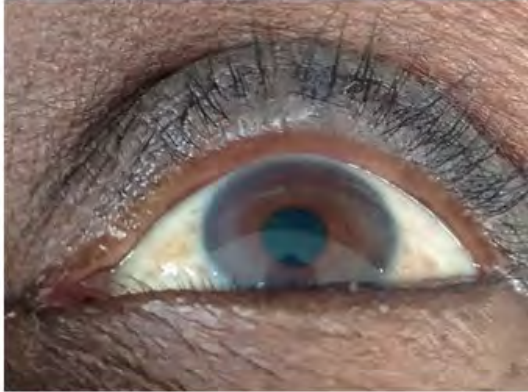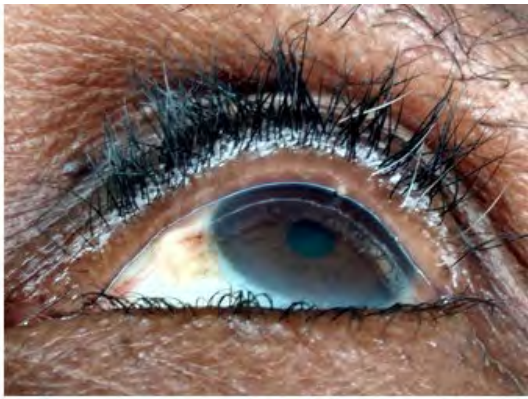Fig. 19. Examples of correct eyelid surgery outcomes

Immediate postoperative appearance



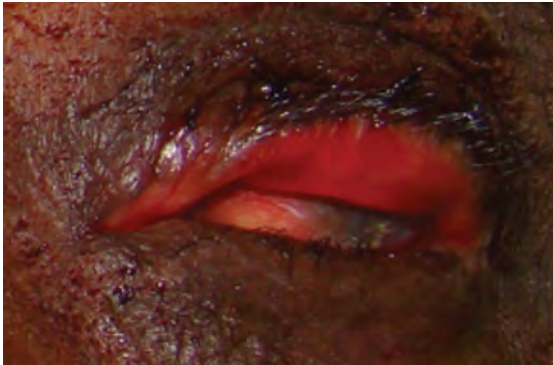
6-Week Outcome



- (ii) If the eyelid looks either undercorrected or overcorrected (Fig. 20, left column), follow the instructions in the figure legend to adjust the tension and if necessary, remove and replace one or more sutures. If knots are too tight, there is a risk of eyelid necrosis.

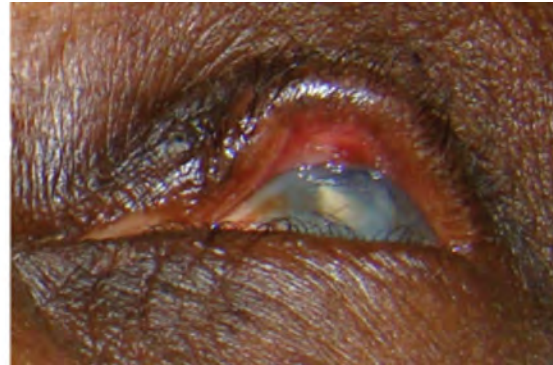Fig. 20. Examples of eyelids with surgical problems

Immediate postoperative appearance

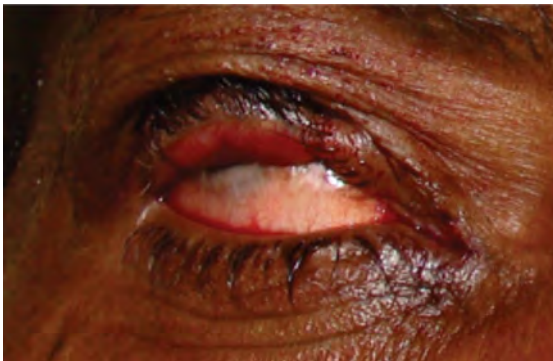

Problem: Over-rotation – cut edge of lower half of tarsus showing
Possible Causes:
 Sutures are too tight
 Incision is too high
 Skin/muscle bites too close to the eyelashes
 Tarsal bites too high

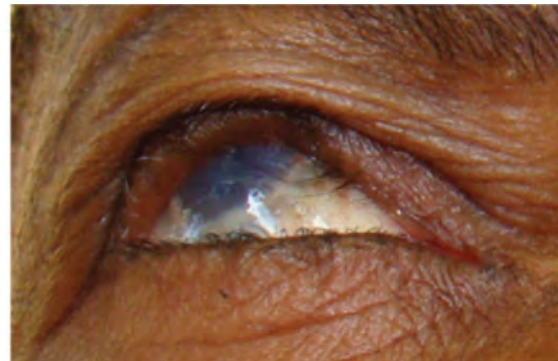
6-Week Outcome



Result: Severe eyelid contour abnormality
Immediate postoperative solution:
 Loosen sutures, if still present then replace the sutures with the skin/muscle bites and the tarsal bites closer to the incision



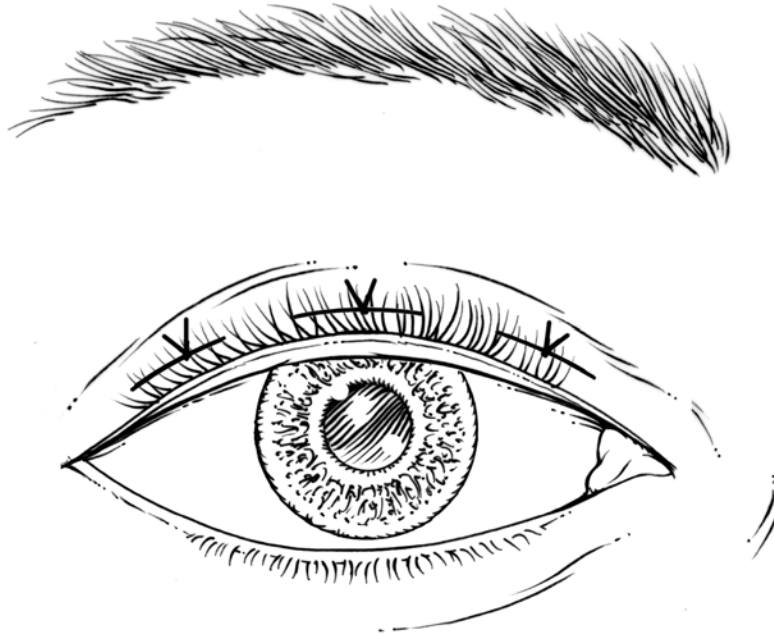
Problem: Under-rotation nasally– eyelashes close to the eye nasally
Possible Causes:
 Sutures too loose
 Incomplete incision nasal side
 Skin/muscle bites too close to the incision
 Tarsal bites too low



Result: Nasal recurrence
Immediate postoperative solution:
 Tighten sutures, if trichiasis still present then nasal incision on nasal side and replace sutures with skin/muscle bites and the tarsal bites farther from the incision

(iii) If the eyelid looks like the “Immediate postoperative appearance” photos in Fig. 19, with a uniform contour and a slight overcorrection along the entire eyelid, complete the knots with two single throws to create a surgical knot. Cut the sutures 3 mm above the knot (Fig. 21). This is long enough to permit ready removal, without being so long as to irritate the eye. If the skin is not well-approximated, two or three skin sutures can be placed in between the rotating sutures by passing the needle into the skin 1 mm from the cut edge, across the wound, and emerging from the skin 1 mm from the other cut edge. The ends are tied without tension and cut.

Fig. 21. Bilamellar tarsal rotation procedure: sutures knotted and cut



11.2 Posterior lamellar tarsal rotation (modified Trabut) procedure

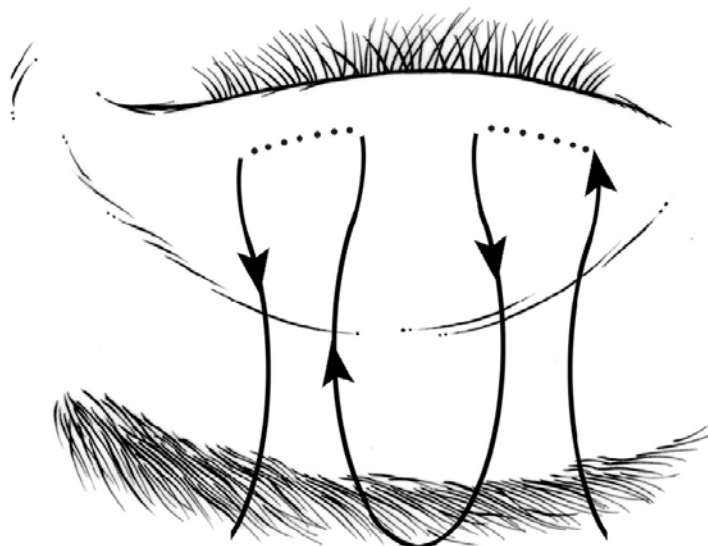
In the posterior lamellar tarsal rotation (modified Trabut) operation, the eyelid is fixed on the Trabut plate, incised through the conjunctiva and tarsal plate, parallel to the eyelid margin. The incision does not include the skin and orbicularis muscle. The muscle is dissected from the tarsal plate in both fragments, and the fragments are re-sutured so that the eyelid margin is rotated outwards and the eyelashes no longer touch the eyeball.

The operation is performed with the surgeon seated at the head of the patient (see Fig. 5). A sterile drape is placed over the patient's face, revealing the eye through the central opening. An assistant (to hand instruments to the surgeon as required) could simplify the operation but is not absolutely necessary.

11.2.1 Placing the traction suture

- (a) A 4/0 silk suture with a needle is used in conjunction with a Trabut plate and a haemostat to fix the eyelid and keep it in an everted position. Insert the needle 3 mm above the eyelashes through the skin and orbicularis of the upper eyelid and take a 5 mm bite horizontally starting from the temporal side.
- (b) Leave a big loop and take a second 5 mm bite two-thirds of the way to the nasal side, coming out at the nasal side.
- (c) The traction suture has two ends, temporally and nasally, with a loop of suture in the middle that covers the distance about one-third of the eyelid (Fig. 22).

Fig. 22. Posterior lamellar tarsal rotation (modified Trabut) procedure: placement of traction suture*

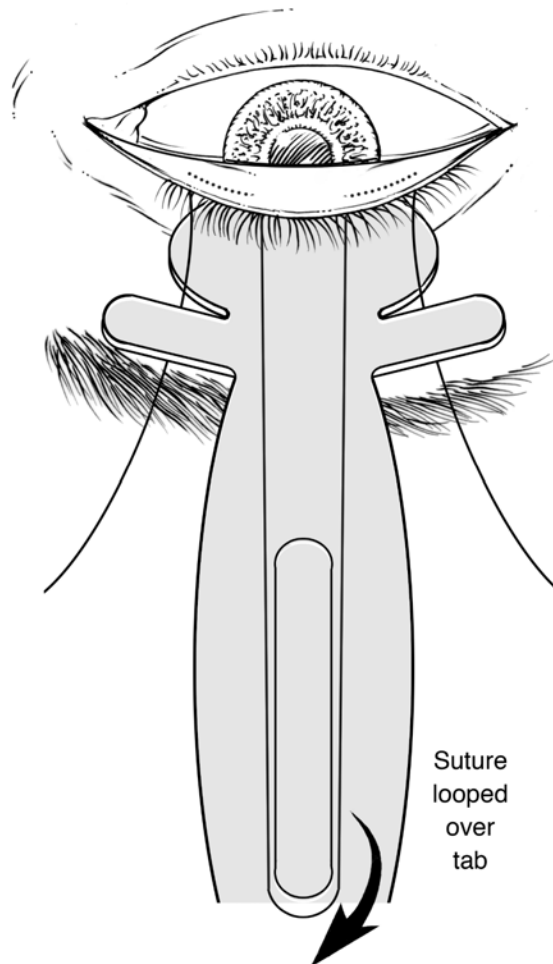


*This and figures 23–35 are of the right eye, from the perspective of the surgeon at the head of the bed. Drawings and descriptions assume that the surgeon is right-handed. Discussion between trainer and trainee will aid translation of these materials for use by left-handed surgeons and for operating on the left eye.

11.2.2 Stabilizing the upper eyelid on to the Trabut plate

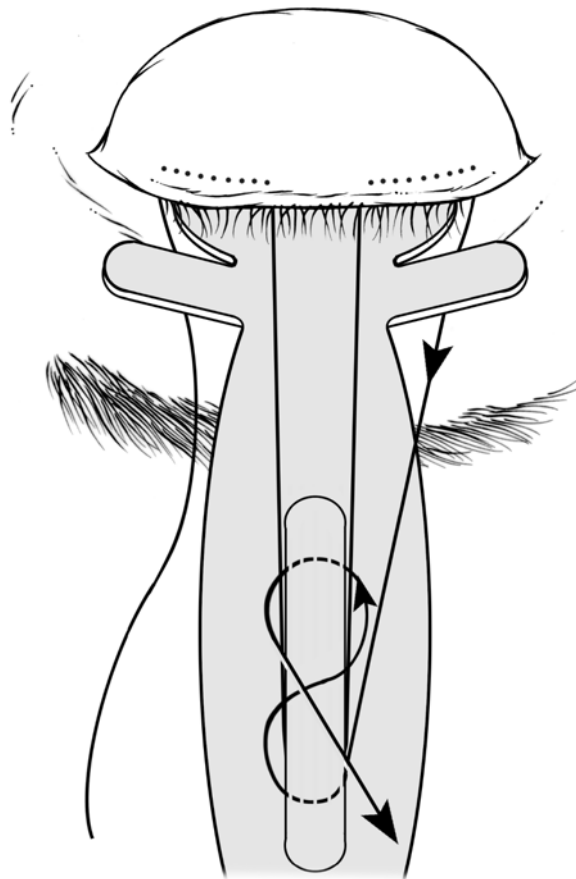
- (a) Hold the Trabut plate with the central tab facing towards you.
- (b) Pull the loop in the middle of the traction suture and hitch it onto the tab of the Trabut plate (Fig. 23).
- (c) Hold the Trabut plate on the eyelid with the tab facing away from you and continue to pull at the two suture ends until the Trabut plate is firmly in contact with the eyelid.

Fig. 23. Posterior lamellar tarsal rotation (modified Trabut) procedure:
placing the suture over the Trabut plate



- (d) Flip the plate towards you while still keeping the tension on the traction suture thereby everting the eyelid. The eyelid should evert easily, if not rearrange the position of the Trabut plate and try again. Secure the suture around the tab (Fig. 24).

Fig. 24. Posterior lamellar tarsal rotation (modified Trabut) procedure:
securing the traction suture

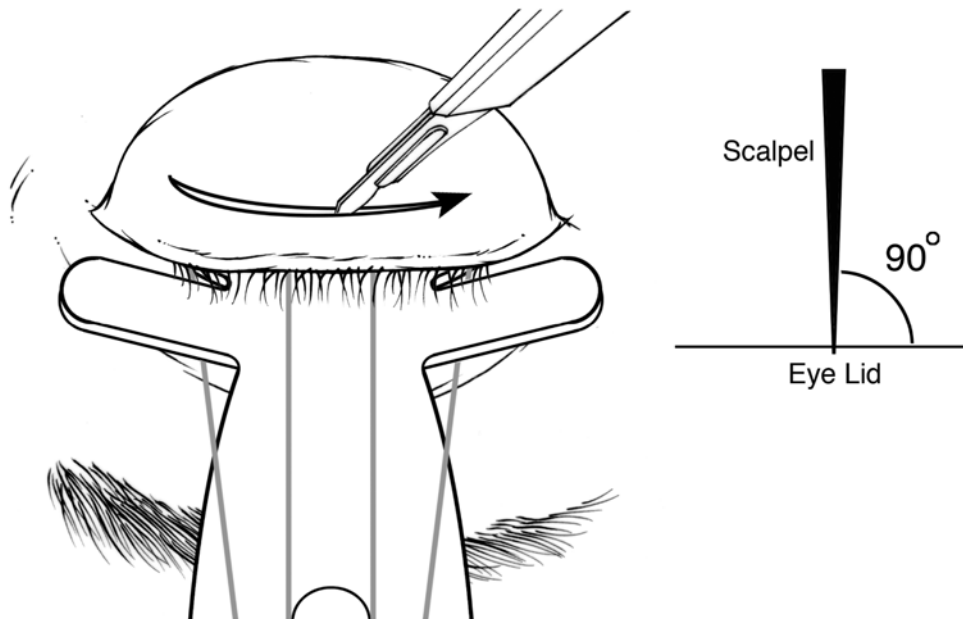


- (e) Fix the sutures with an artery forceps to the drape to secure the Trabut plate and the everted eyelid in position.

11.2.3 Making the incision

- (a) Holding the blade perpendicular to the conjunctiva, starting 2 mm lateral to the punctum, make a curvilinear cut 3 mm from the eyelid margin on the tarsal conjunctiva. Cut through the conjunctiva and the tarsal plate but not through the muscle (Fig. 25).

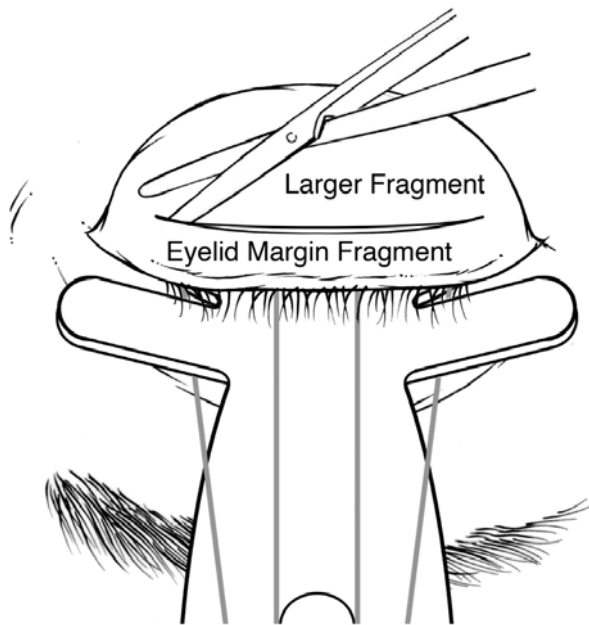
Fig. 25. Posterior lamellar tarsal rotation (modified Trabut) procedure: incision through conjunctiva and tarsal plate



- (b) Complete the cut with curved scissors if needed (Fig. 26).

DO NOT CUT THE PUNCTUM OR CUT THROUGH THE EYELID MARGIN

Fig. 26. Posterior lamellar tarsal rotation (modified Trabut) procedure:
cutting with scissors

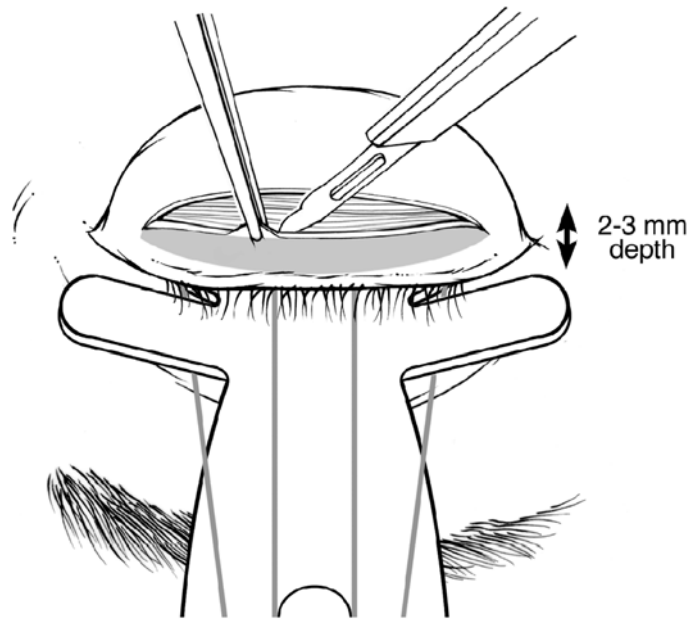


(c) We shall call the fragment with the upper eyelashes the EYELID MARGIN FRAGMENT and the other fragment the LARGER FRAGMENT.

11.2.4 Dissecting the eyelid margin fragment

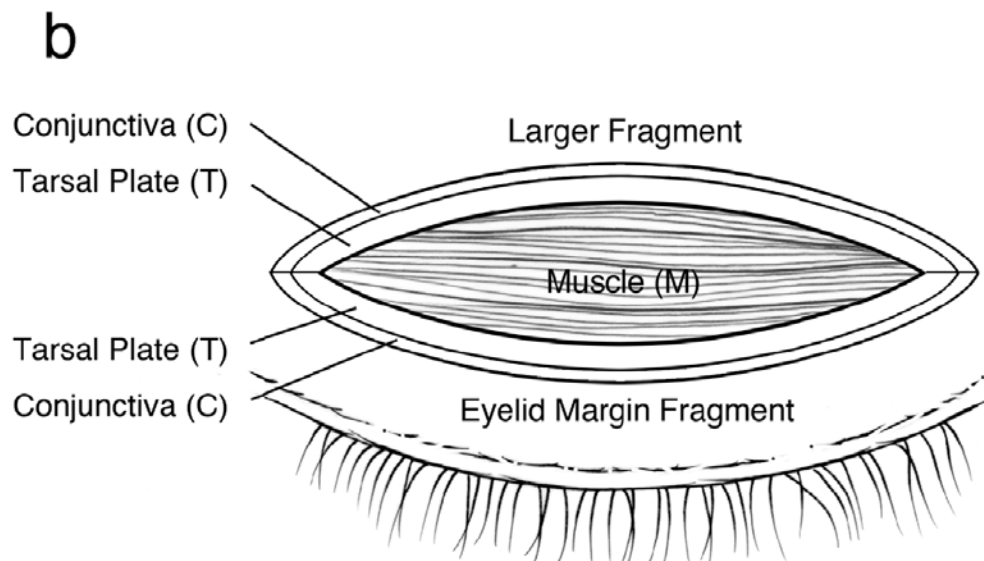
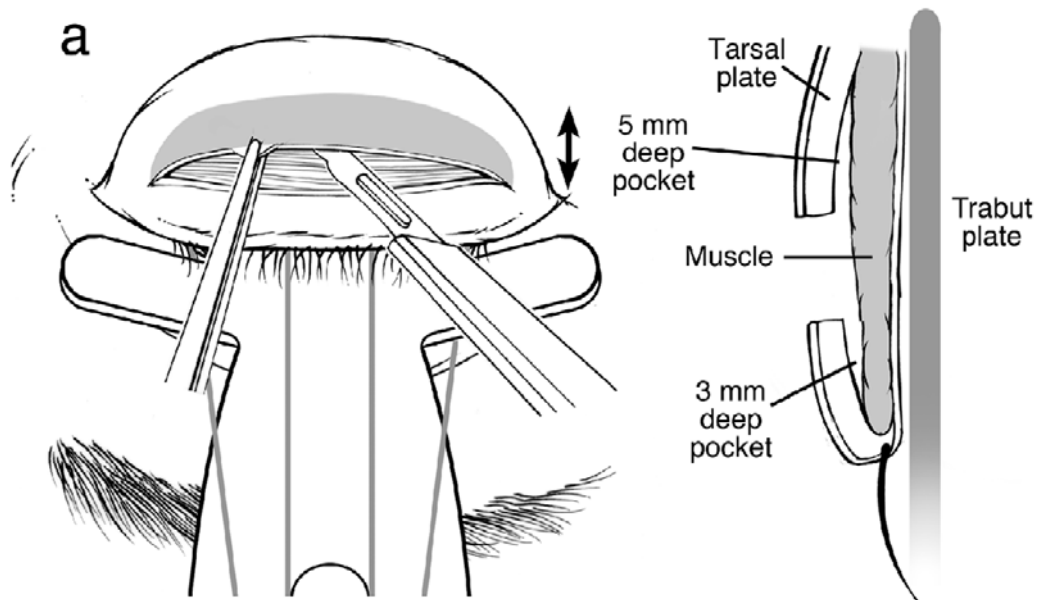
- (a) Hold the cut edge of the eyelid margin fragment up, and using the blunt side of the blade or blunt-tipped scissors, gently dissect the orbicularis muscle away from the tarsal plate. Create a pocket between the orbicularis and the Tarsal plate about 2–3 mm deep (Fig. 27).

Fig. 27. Posterior lamellar tarsal rotation (modified Trabut) procedure: dissection of eyelid fragment



- (b) Once you have created the pocket, use the forceps to stabilize the cut edge of the larger fragment and dissect the orbicularis muscle away from the tarsal plate for about 5 mm (Fig. 28a and b).

Fig. 28a and b. Posterior lamellar tarsal rotation (modified Trabut) procedure:
dissection of the larger fragment

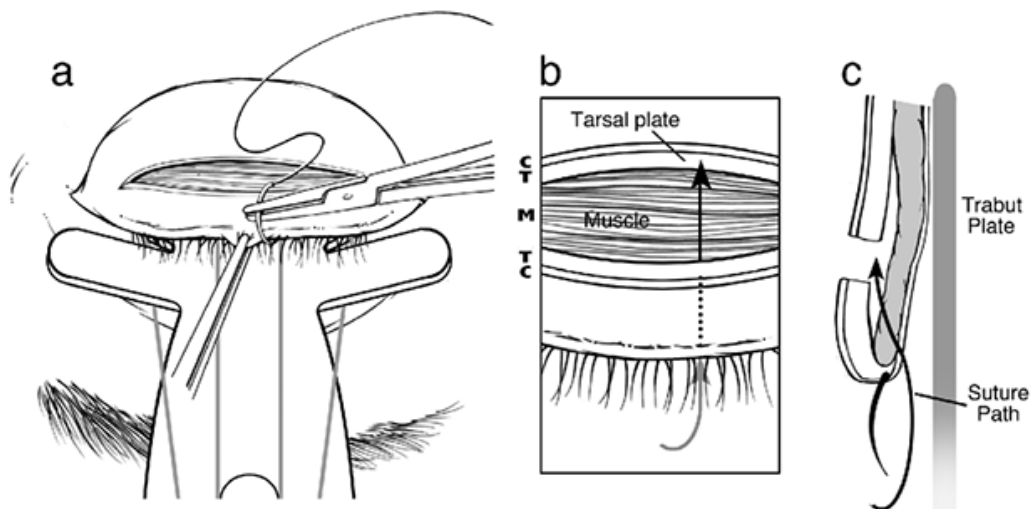


11.2.5 Suturing the eyelid margin fragment

(a) Centre Suture

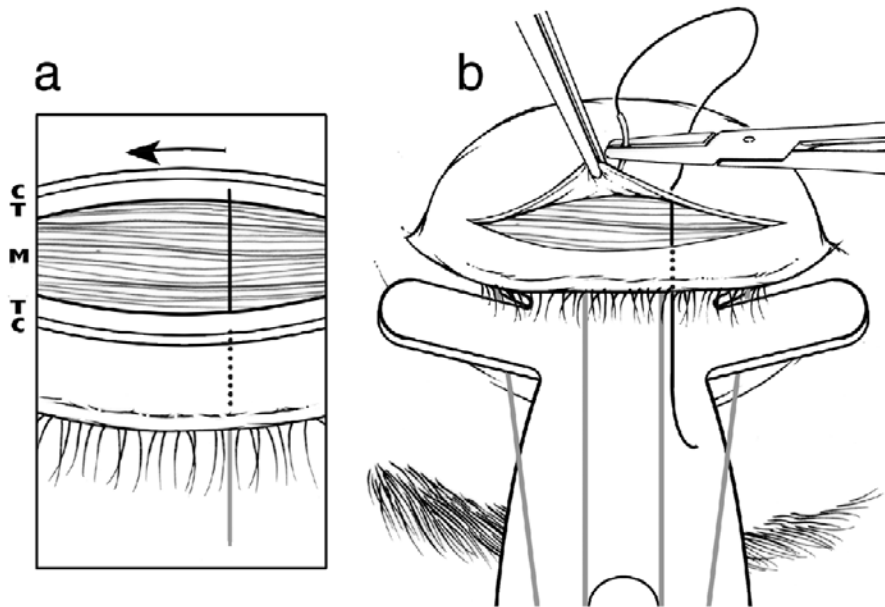
- (i) To start suturing, imagine the incision length of the larger fragment eyelid in five sections, with three of them being the stitches and two of them being the space between the stitches.
- (ii) Using the needle holder, mount the needle away from you. Use the toothed forceps to pick up the eyelid margin fragment at approximately the centre of the incision length. If you are a right-handed surgeon operating on the right eye of a patient, take the first suture bite at about 2 mm temporal to the toothed forceps, starting in the eyelid margin fragment about 1 mm below the eyelashes on the skin side, through the skin and muscle to emerge in the pocket behind the tarsus, not through the tarsus (Fig. 29a, b & c). (If you are left-handed surgeon operating on the right eye of a patient, take the first suture bite at about 2mm nasal to the toothed forceps.)

Fig. 29a, b and c. Posterior lamellar tarsal rotation (modified Trabut) procedure: centre suture in eyelid margin fragment (conjunctiva, C; tarsal plate, T; muscle, M)



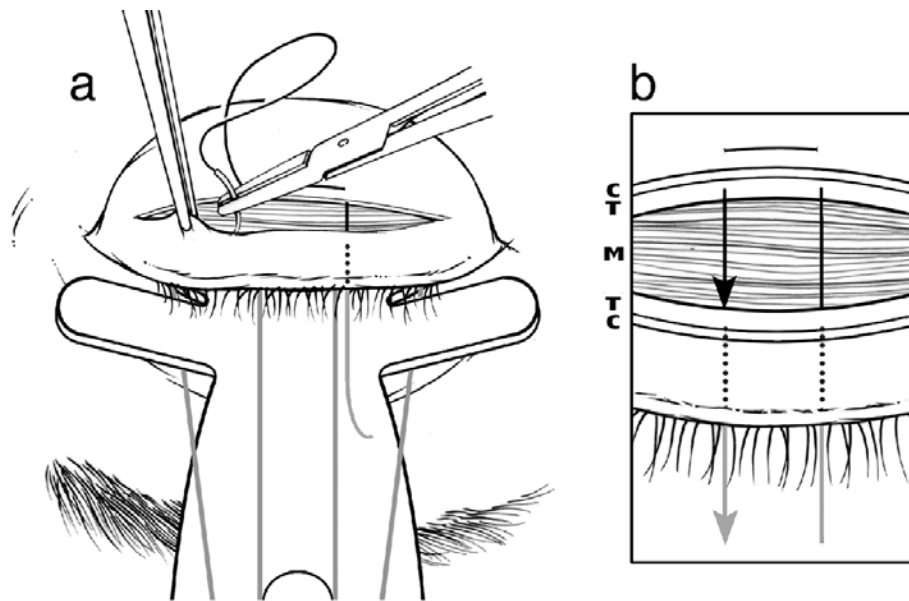
- (iii) Grasp the cut edge of the tarsal plate in the larger fragment with the toothed forceps and rotate it slightly towards you (Fig. 30a). Pass the needle into the white cut edge of the tarsal plate about in the middle (half thickness). Gently guide the needle so it emerges from the tarsal plate through the conjunctiva at a point about 1.5 mm from the cut edge (Fig. 30b).

Fig. 30a and b. Posterior lamellar tarsal rotation (modified Trabut) procedure: centre suture in larger fragment (conjunctiva, C; tarsal plate, T; muscle, M)



- (iv) Note the suture entrance into the cut edge of the tarsus should line up straight with the exit of the suture just placed through the eyelid margin fragment. Complete the first larger fragment suture by holding the tarsus with toothed forceps. Hold the needle so it is facing you and take a bite through the conjunctiva 1.5 mm from the cut edge and in line with, but about one-fifth of the incision length away from, the suture exit. Push the needle through the inside of the tarsus at half thickness. Gently guide the needle so it emerges through the cut edge.
- (v) Keeping the needle straight, proceed to the eyelid margin fragment, and pass through at the bottom of the pocket behind the tarsus (not through the tarsus) and exit at the eyelid margin 1 mm below the eyelashes from where you are seated at the head of the patient (Fig. 31a and b). Pull the needle through and leave enough suture to tie, cut the suture. The centre suture is complete.

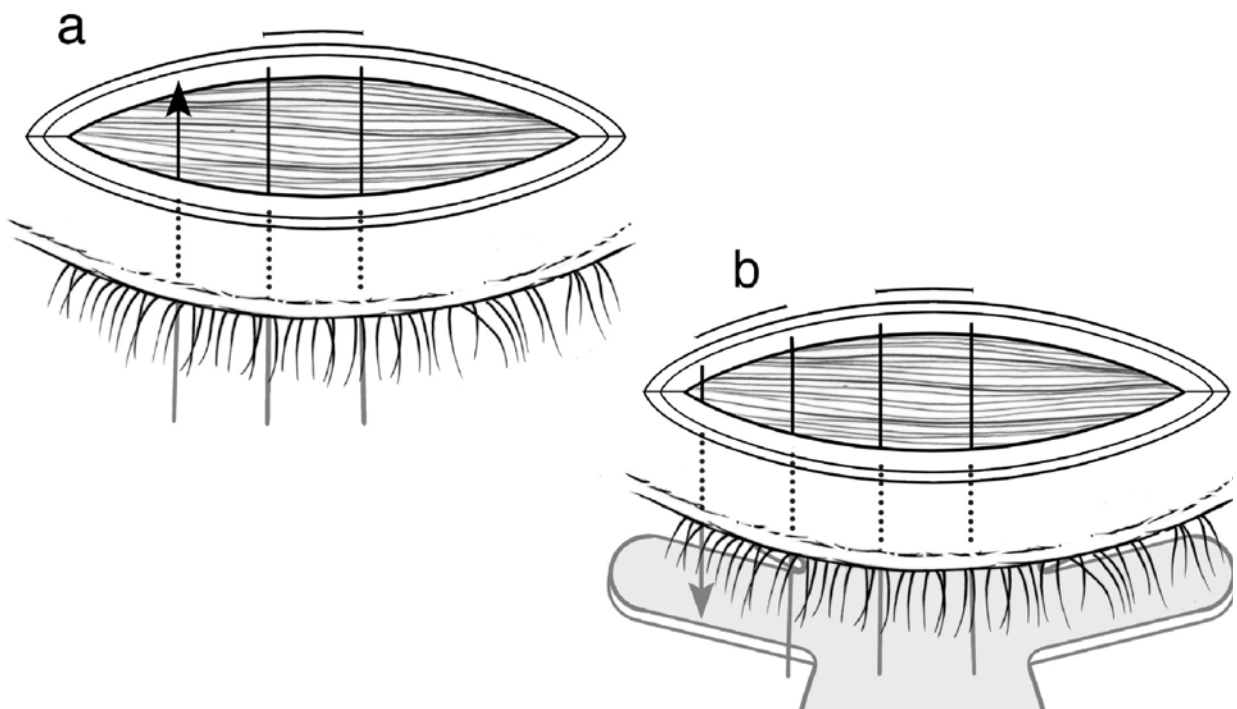
Fig. 31a and b. Posterior lamellar tarsal rotation (modified Trabut) procedure: completing the centre suture (conjunctiva, C; tarsal plate, T; muscle, M)



(b) Second Suture

- (i) Take another bite of the eyelid margin, 1 mm below the eyelashes on the skin side, as in the first suture, but at least 5 mm from the first suture. Proceed as described above for the first suture (Fig. 32a and b).

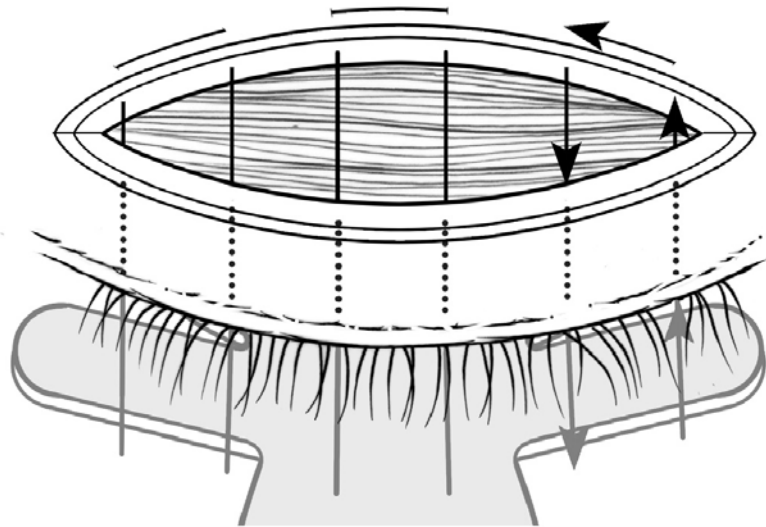
Fig. 32a and b. Posterior lamellar tarsal rotation (modified Trabut) procedure: starting and completing the second suture



(c) Third Suture

- (i) The third suture is done exactly as above only on the other side of the eyelid.
- (ii) At this point, there are six sutures exiting the eyelid fragment margin, equally spaced and parallel to each other (Fig. 33).

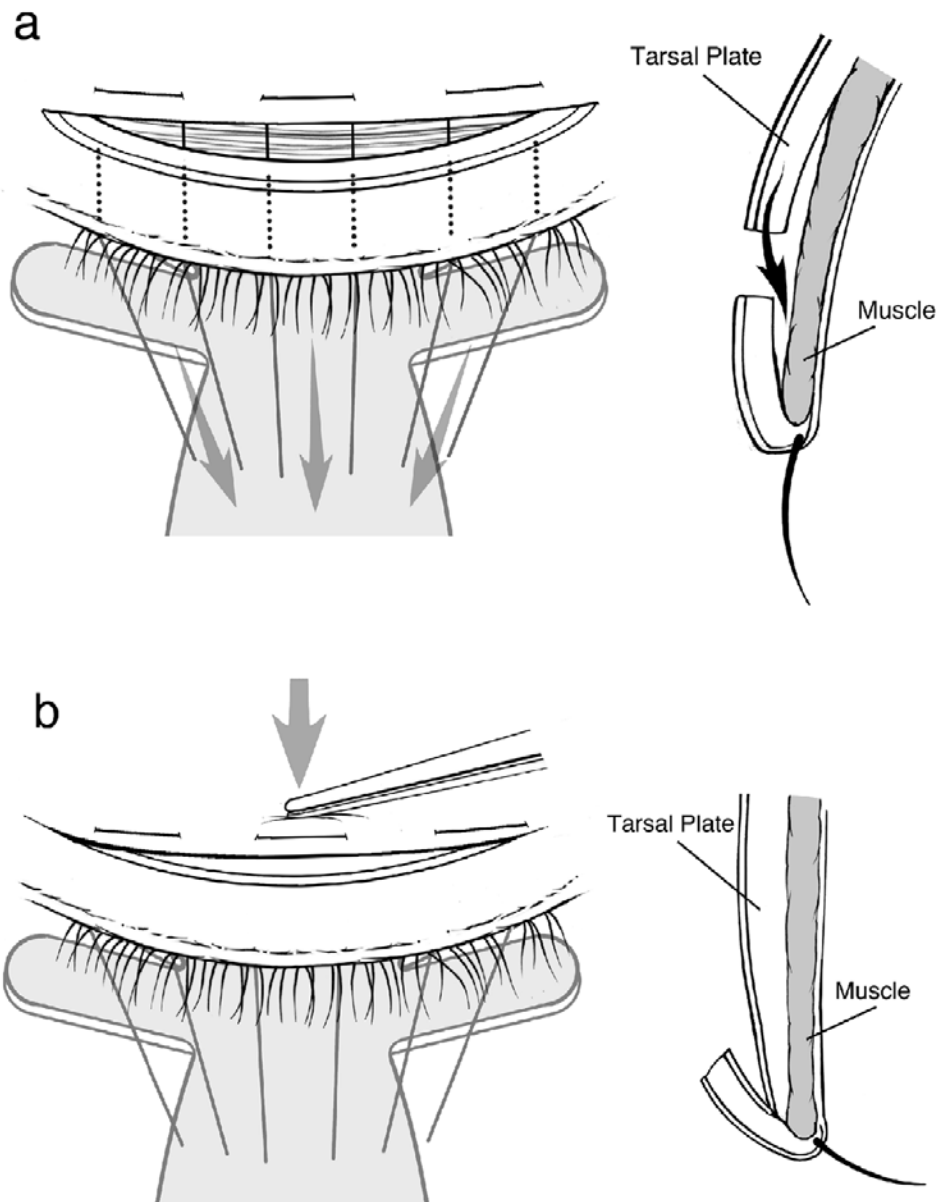
Fig. 33. Posterior lamellar tarsal rotation (modified Trabut) procedure: third suture



(d) Pulling the Sutures

- (i) Start to pull the sutures up towards the plate, which should draw the larger fragment tarsus INTO the pocket of the eyelid margin fragment (Fig. 34). Use the forceps or bottom of the blade handle to gently guide the larger fragment tarsus into the pocket.

Fig. 34a and b. Posterior lamellar tarsal rotation (modified Trabut) procedure:
pulling sutures and guiding fragment



- (ii) Done correctly, the stitches should not be visible, and the incision line should be curvilinear.

(e) Tie the sutures

- (i) **TIE THE CENTRAL SUTURE** with the first double throw of a surgical knot. Then tie the other two sutures in the same way (Fig. 35). Remove the Trabut plate but leave behind the traction suture in case it is needed. Adjust the tension of the sutures to produce the desired **SLIGHT OVERCORRECTION** as viewed from below. Once the desired result is achieved, remove the traction suture and continue with the second and third single throws of the surgical knot starting with the central suture followed by the nasal or temporal sutures. Cut the sutures 3 mm above the knots (Fig. 36).

Fig. 35. Posterior lamellar tarsal rotation (modified Trabut) procedure: tying knots

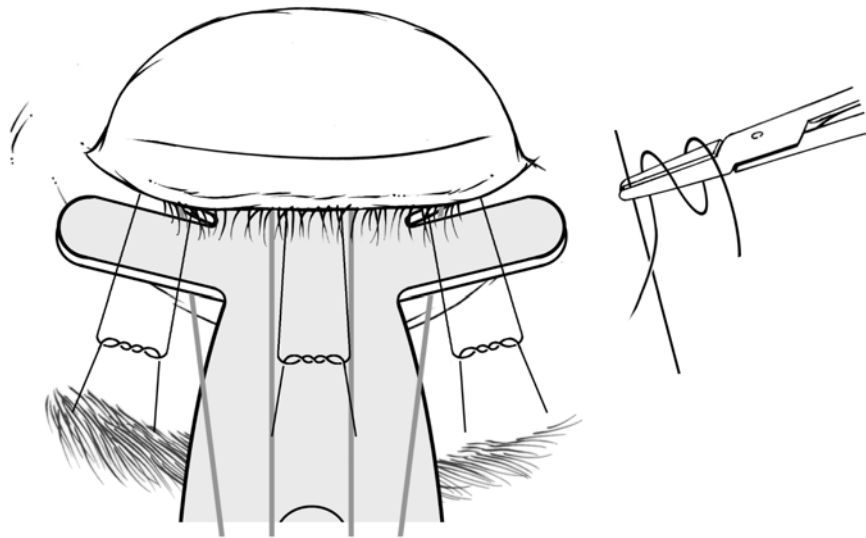
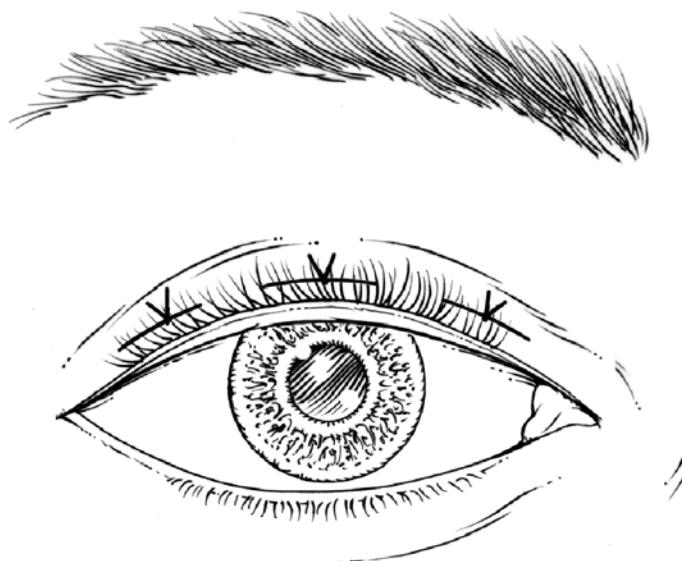


Fig. 36. Posterior lamellar tarsal rotation (modified Trabut) procedure: sutures knotted and cut



- (f) If the eyelid looks like Fig. 19, left column (see bilamellar tarsal rotation section), the surgery will most likely be successful.
- (g) If the eyelid looks like Fig. 20 (see bilamellar tarsal rotation section), then follow the instructions in the figure legend to adjust the tension and if necessary, remove and replace one or more sutures.

11.3 Possible surgical difficulties

- (a) **Bleeding.** If bleeding cannot be controlled by pressure with a gauze swab, the MARGINAL ARTERY, which runs along the eyelid margin, may have been cut. This usually occurs nasally, and blood will be seen pulsating from a single source. Locate this source, clip a haemostat onto it, and tie an absorbable suture just below the haemostat to close the artery. Otherwise, oversew the area with a suture.
- (b) **Division of the eyelid margin.** This is most unlikely with careful surgery but, should it occur, the cut portions of the eyelid margin fragment must be sutured together. Place one absorbable suture in the eyelid margin, so that its edges match exactly. Tie the suture without tension, with three single knots. Place one or two separate sutures on the outer surface of the tarsal plate. If the skin has also been divided, it may be sutured with one or two separate sutures. If the repair is satisfactory, proceed with the operation. If not, refer the patient to an ophthalmologist at once.
- (c) **Overcorrection:** If procedures have been followed carefully and the surgeon has looked at the eyelid and made the necessary adjustments to achieve the desired slight overcorrection before tying the knots completely, this should not be an issue. However, if the eyelid margin is grossly everted, remove the sutures and repeat the suturing. This time, tie the sutures with less tension to achieve the desired slight overcorrection.
- (d) **Undercorrection.** If procedures have been followed carefully and the surgeon has looked at the eyelid and made the necessary adjustments to achieve the desired slight overcorrection before tying the knots completely, this should not be an issue. If the eyelashes still touch the eyeball, remove the sutures, and check for proper dissection of the distal and proximal fragments. Complete the dissection if necessary and repeat the suturing. Tie the sutures with more tension to achieve the desired slight overcorrection.

PRACTICE: THE TRAINEE SHOULD LIST SURGICAL COMPLICATIONS AND SOLUTIONS

11.4 **Applying the antibiotic and dressing**

- (a) Apply tetracycline ointment into conjunctival sac and onto the wound.
- (b) Pad the eye. An elastic bandage may also be used over the eye pad if there is a need to apply pressure to avoid bleeding.
- (c) Give a single 1 g dose of azithromycin, if available.

11.5 **Give analgesic tablets and inform about follow up**

- (a) Provide two 500 mg tablets of acetaminophen (paracetamol) for pain. Inform the patient that pain may return after the local anaesthetic injection wears off. Give the patient eight more 500 mg paracetamol tablets to take home. He or she may take two tablets every 6 hours if needed to control pain.
- (b) Advise the patient to rest quietly at home and to return the next day for assessment of the surgical site. The patient should also return 8–14 days after surgery for suture removal and/or a check of the surgical site.

11.6 **Safe disposal of sharps**

In order to avoid accidents with used needles or blades, they must be properly disposed of in a designated sharps disposal container.

11.7 **Disinfecting, cleaning and sterilizing the instruments**

- (a) After the operation has been performed, the instruments are disinfected first by placing in a disinfectant solution for 10 minutes before being cleaned with water, detergent and a brush to remove any blood or debris.
- (b) The cleaned instruments are rinsed with water, dried and then sterilized using an autoclave or a hot air sterilizer, as described previously.

12. Postoperative care

LEARNING OBJECTIVE: TO BE ABLE TO ASSESS RESULTS AND MANAGE COMPLICATIONS OF THE BILAMELLAR TARSAL ROTATION AND/OR POSTERIOR LAMELLAR TARSAL ROTATION (MODIFIED TRABUT) PROCEDURES

12.1 At day 1: Check the wound and eyelid correction.

The first postoperative day follow-up should be done by the surgeon who performed the surgery.

- (a) Remove the pad and clean the eye with gauze and saline. The eyelid may be swollen.
- (b) Assess the status of eyelid correction. The properly corrected eyelid should have a slight overcorrection. If there is undercorrection or overcorrection, the surgeon must explain the situation to the patient and surgery should be revised the same day.
 - (i) Undercorrection. Follow proper surgical techniques to disinfect and drape the patient and inject local anaesthetic. Depending on the assessment of the eyelid, remove one or more sutures if indicated. If the posterior lamellar tarsal rotation (modified Trabut) procedure was performed, check for proper dissection of the distal and proximal fragments, and complete dissection if necessary. Reapply the sutures in such a way that they are closer to the eyelid margin and tie the sutures firmly to produce the desired slight overcorrection.
 - (ii) Overcorrection. Follow proper surgical techniques to disinfect and drape the patient and inject local anaesthetic. Depending on the assessment of the eyelid, remove one or more sutures if indicated. If the posterior lamellar tarsal rotation (modified Trabut) procedure was performed, check for proper dissection of the distal and proximal fragments, and complete dissection if necessary. Reapply the sutures in such a way that they are further from the eyelid margin and tie the sutures gently to produce the desired slight overcorrection.
- (c) Apply tetracycline ointment between the lower eyelid and the eyeball. Show the person who is accompanying the patient how this is done, so that he or she can apply ointment twice daily for seven days at home.

12.2 At day 8–14: Remove the sutures (if absorbable sutures were used, the wound should still be examined).

- (a) Clean the eye with gauze and saline.
- (b) Gently pull on the knot with forceps.
- (c) Insert scissors or a blade under the knot so that only ONE SIDE of the suture is cut. DO NOT CUT BOTH SIDES OF THE LOOP because when you remove the knot, part of the suture will remain in the eyelid. Retained sutures are a major cause of infection and granulomata.

- (d) Remove the sutures by gently pulling on the knotted end of the suture.
- (e) Check for local infection. If pus is seen on the wound, remove any involved sutures and clean with gauze and boiled water. Advise the patient to do this three times daily for 1 week.
- (f) Check for cellulitis. If there is pain, spreading redness of the eyelid, fever and rapid pulse rate, GIVE ANTIBIOTICS SUCH AS AMPICILLIN, BY MOUTH AND REFER TO A DOCTOR URGENTLY. HOSPITAL ADMISSION MAY BE NEEDED.
- (g) Check for eyelid closure defects. If the eyelids do not close properly when the patient tries to close them gently, as if in sleep, or the cosmetic appearance is very distressing, REMOVE THE SUTURES AND MASSAGE THE UPPER EYELID DOWNWARDS. If this does not correct the problem, refer the patient to an ophthalmologist for a second operation. DEFECTIVE EYELID CLOSURE IS A SERIOUS CONDITION. Note that this should have been corrected at the end of the surgical procedure.

12.3 At 6 weeks to 6 months.

- (a) A granuloma looks like a red lump on the conjunctiva of the upper eyelid tarsus. The development of a granuloma requires surgical excision for comfort because a granuloma can distort the eyelid and can cause chronic discharge from the eye. The granuloma can be excised with a scalpel or scissors after applying anaesthetic drops and everting the eyelid. Any remaining suture at the site should be removed if present.
- (b) Necrosis is death of part of the eyelid margin usually as a result of poor blood supply caused by an incision made too close to the eyelid margin. While the area of necrosis will eventually heal without any treatment, a loss of a part of the eyelid margin can result. Therefore, the patient should be closely monitored for possible development of an eyelid closure defect.

13. Results

LEARNING OBJECTIVE: TO LEARN HOW TO RECOGNIZE SUCCESSFUL AND UNSUCCESSFUL SURGICAL OUTCOMES, AND HOW TO MANAGE ADVERSE OUTCOMES

Complete success is defined as NO EYELASHES TOUCHING THE EYEBALL (in the absence of epilation or further surgery) WITHOUT AN OBVIOUS OVERCORRECTION and WITH NO COMPLICATIONS such as a severe eyelid contour abnormality by six months (see Fig. 20 for examples of severe contour abnormalities). Patient satisfaction with the outcome should also be assessed.

If one or two eyelashes at the medial or lateral edge of the eyelid continue to touch the eyeball after surgery, they may not need to be managed by repeat surgery. Epilation is a possible management option.

If any eyelashes continue to touch the cornea, if there is still sufficient trichiasis to cause discomfort, or if there is renewed corneal damage from persistent misdirected eyelashes, further surgery is indicated. REFER THE PATIENT TO AN EXPERIENCED TT SURGEON OR AN EXPERIENCED OPHTHALMOLOGIST for further surgery.

Part Two

For trainers

14. Introduction

Part Two of the manual is designed for the trainers of candidate TT surgeons and covers selection and final assessment of the candidates. It does not cover the logistics of setting up a training programme. Rather, it is intended to be used by an experienced trichiasis surgeon trainer, preferably an ophthalmologist with theoretical and surgical background, to certify non-ophthalmic surgeons as competent to perform the bilamellar tarsal rotation procedure or posterior lamellar tarsal rotation (modified Trabut) procedure on their own.

14.1 Objectives

- (a) To identify good candidates for training
- (b) To list and describe the knowledge that must be demonstrated and the procedures that must be successfully completed before, during, and after, surgery in order for certification to be granted
- (c) To provide a checklist of the knowledge and procedures to assess during observation of the surgical process
- (d) To provide guidelines for scoring the checklist for purposes of certification

14.2 Who Should Be Trained?

Trainees are expected to be eye surgeons; physicians with surgical experience; eye care or surgical nurses; or eye care assistants. General medical assistants with some surgical background may be considered but may need more background in the anatomy and examination of the eye. Trainees should have: :

- (a) Previous experience with eye examination
- (b) Experience in giving injections
- (c) Knowledge of sterile surgical techniques
- (d) Demonstrated ability in manual dexterity (stable hands and able to place even stitches during an initial training on a mannequin-based platform, a piece of thick material, or an orange peel)
- (e) Near vision of 20/20 with available correction

14.3 Expected training

A minimum requirement is 15 eyes with TT per trainee for training; plus 2 eyes with TT for every 2 trainees for initial demonstration of appropriate technique by the trainer.

There is also the assumption that the trainer or another surgeon has carried out TT surgery 1–2 weeks prior to the training programme so that the trainees can practice removing sutures acceptably. During each section in this manual, there are objectives and practice sessions that can be held in a classroom setting the first day, with clinical days on subsequent days. Below is a possible programme of 5 days. There should be a maximum of 6 trainees per trainer in any one 5-day programme. In total, each trainee should operate on at least 15 eyes as part of the training programme, at least 5 of which should be completed independently as part of certification.

- (a) **Day 1:** Read the training booklet and carry out the exercises and practice sessions together.
- (b) **Day 2:** The trainer and trainees examine patients, observe the trainer perform TT surgery on at least two eyes (at least one right eye and one left eye), and, if deemed ready, the trainees assist in the operation of five more eyes with increasing responsibility. At any one time, no more than two trainees should be observing or assisting the same trainer; other trainees involved in the training programme could be observing or assisting other trainers or practicing their skills elsewhere.
- (c) **Day 3 and 4:** Trainees observe the outcomes of the previous day and set up the entire operation for the day, from sterilization to closure, but under supervision. At least 10 eyes should be operated on in total per trainee on days 2, 3 and 4, including a mix of right and left eyes. Within these 10 eyes, at least 2 eyes should be operated on by each trainee without the need for intervention by the trainer. Trainees should also remove sutures from trainer's cases done prior to the start of training.

If, after operating on 10 eyes, a trainee cannot perform surgery independently, then the trainer must inform the trainee that they cannot be certified and therefore cannot perform TT surgery. This is the most difficult step for many trainers, but is **ESSENTIAL** from an ethical perspective. Trainees who cannot be independent or who fail final assessment must not be allowed to do surgery.
- (d) **Day 5:** If the trainer feels the trainee is ready, day 5 will be devoted to final assessment.

15. Final assessment of TT surgeons

15.1. Using this Section

This section presumes that the original trainer is conducting the final certification. If, for some reason, the examiner is NOT the trainer, the examiner will presume that the trainee was provided with all the information in Part One of this manual and has completed the training surgeries independently. For certification, the examiner should observe each trainee carrying out five bilamellar tarsal rotation or posterior lamellar tarsal rotation (modified Trabut) procedures (i.e. surgery on five eyelids, with a mixture of right and left eyes). The trainee must undertake the subsequent five procedures alone, without comment or intervention by the examiner (unless such intervention becomes necessary for the safety of the patient).

15.2. Qualifications for certification

In order to become certified in the bilamellar tarsal rotation or posterior lamellar tarsal rotation (modified Trabut) procedures, the trainee must have accomplished the following:

- (a) Completed training in TT surgery in a course of accepted minimum depth and practical content (depending on national policy) and have done at least 10 eyelid surgeries independently;
- (b) Received a recommendation for certification from the trainer; and
- (c) Successfully performed 5 sequential trichiasis operations under observation by the examiner, defined as fewer than 10 unsatisfactory marks on the checklist and none in the critical areas (those marked in yellow with a star*).

15.3. Knowledge and procedures to be assessed

The following material focuses on knowledge and procedures before surgery, then the bilamellar tarsal rotation and posterior lamellar tarsal rotation (modified Trabut) procedures. It includes a detailed description of each item on the checklist, and comprehensive guidelines for assessing the trainee. The knowledge base can be assessed at the time of the first operation and need not be repeated for successive operations unless the examiner deems it necessary. All other assessments must be made at every operation. The items marked with a star (*) are critical and must be correctly performed in every case if the trainee is to achieve certification.

15.4. Before surgery

- (a) *Setting up the surgical space.* The trainee should ensure that the surgical bed and surgical trolley are properly arranged given the size and layout of the surgical space, ensure adequate lighting for surgery and ensure that all necessary equipment for conducting surgery, including a rubbish bin and sharps disposal box, is readily available.
- (b) *Assembly of materials before surgery.* The trainee should demonstrate assembly of the necessary materials and consumables, preparing and setting them up on a table before surgery (see section 7.2).
- (c) *Knowledge of surgical material.* The trainee should be able to identify each instrument or material, know what it is used for, how it is used, and why it is needed.

15.5. Sterilization of equipment before use

- (a) **Knowledge of sterile techniques.* The examiner must ask questions on the definition of sterile, why sterility is necessary, details of techniques for achieving sterility, and alternatives to use in the local setting if the usual technique is not available. For example, if the health centre is using an autoclave, the trainee must be able describe the use of the autoclave, the cleaning and disinfecting of the instruments, the loading of the autoclave, the duration of autoclaving after a temperature of 121 °C is reached, and sterilization alternatives if the autoclave is not working (e.g. pressure cooker autoclave for sterilization of the instruments and materials).
- (b) **Appropriate sterilization of all non-disposable instruments and materials.* The examiner should observe performance of the sterilization procedure and note whether sterility is achieved.
- (c) **Maintenance of sterility of sterile items.* The examiner should observe the use of sterile forceps to handle sterile materials in order to maintain sterility.

15.6. Examination of the patient

- (a) *Patient interaction.* The examiner should observe the trainee interacting appropriately with the patient and obtaining or reviewing informed consent for the surgery (if this has not yet been done). Locally appropriate customs for greeting should be observed before any examination is started or the patient is touched.
- (b) *Use of a bright torch and 2.5× surgical loupes to examine the patient.* A bright light should be used to examine the patient to ensure that trichiasis is not missed.
- (c) *Examination of the eyelid from below to look for TT.* The correct position must be used when examining for TT. The patient should have their head level with their eyes looking straight ahead. The trainee should be below the level of the patient's gaze, looking upwards towards the upper eyelid to determine whether trichiasis is present. The trainee should locate the eyelid margin and eyelashes and look from different angles (below, temporal and nasal sides) and determine if any eyelashes from the upper eyelid touch the eyeball, or if there is evidence of recent removal of in-turned eyelashes from the upper eyelid. The trainee should ask the patient look to the right, then to the left, and watch to see if any eyelashes touch the eyeball. The trainee could further use his or her thumb to exert a mild pressure on the patient's upper eyelid so that the eyelid lifts slightly for better evaluation.
- (d) *Examination of the eyelid for the presence of entropion.* The patient must be looking up while the trainee looks for visibility of the eyelid margin. If part or all of the eyelid margin is not visible, the trainee must note that entropion is present.
- (e) **Correct identification of TT and entropion.* The examiner must certify that the trainee has correctly identified the presence or absence of TT and the presence or absence of entropion.
- (f) **Determining whether there is defective eyelid closure.* The examiner must observe the trainee using proper examination technique and what would be done with the patient if an eyelid closure defect were found. In many settings, such patients must be referred to an ophthalmologist for appropriate surgery.

- (g) *Obtaining a relevant medical history from the patient, according to local practice.* The trainee must confirm that the patient will be able to tolerate surgery. This should include ascertaining whether:
 - (i) The patient can lie flat on his or her back for 30 minutes
 - (ii) The patient has other relevant problems, such as a blood disorder that may result in excessive bleeding, any condition that necessitates daily medication (ascertain what condition and what medication is being taken), shortness of breath, or heart problems
- (h) **Correct classification of the patient as a surgical candidate for the trainee.* The patient should fulfil the criteria for indications of TT surgery, should have no other ocular condition that would complicate the surgery, such as eyelid closure defect or grossly infected eyelid, and must be fit to undergo surgery at the community level, under local anaesthesia.

15.7. Preoperative preparation

- (a) *Explanation to the patient.* The trainee explains to the patient what is going to happen. The examiner should hear the trainee clearly state both the problem (e.g. eyelashes turning in) and the solution (corrective surgery). The initial steps, such as injection of the local anaesthetic, should also be explained (e.g. the injection will cause some slight stinging, but the patient should feel no pain). If the examiner does not speak the language used to communicate with the patient, the explanation must be checked by another party.
- (b) *Use of a cap, mask and loupes.* The trainee should put on a cap, a mask and operating loupes. The trainee should adjust his or her loupes before scrubbing their hands.
- (c) *Administration of topical anaesthetic.* The trainee administers the topical anaesthetic. The examiner should observe proper placement of the anaesthetic in the lower fornix, while the patient is looking up.
- (d) *Appropriate handwashing.* The trainee should demonstrate proper surgical hand scrub technique, and the examiner should observe the duration and thoroughness of the scrub. The trainee should use soap and running water if available to wash hands for 5 minutes, followed by use of a disinfectant, to ensure aseptic conditions.
- (e) **Use of sterile gloves to maintain sterility.* The examiner should observe the trainee putting on surgical gloves without contaminating them and note whether his or her fingers, hands, or arms touch any part of the gloves that they should not touch.
- (f) **Preparation of the patient's face and eyelids.* The examiner must observe the use of 10% povidone iodine solution or equivalent solution, with care to avoid getting the povidone iodine in the patient's eyes. The technique of cleaning in a circular pattern, starting at the eyelids and moving outward towards the face must be observed. If the trainee returns to clean the eyelid again, a fresh gauze must be used to prevent contamination from the face to the eyelid area. Then a sterile drape with an appropriately sized hole should be used to cover the face.

15.8. Injecting anaesthetic

- (a) *Inspection of the label.* The label on the bottle should be checked for the name of the drug and the expiration date.
- (b) *Maintenance of sterility of the anaesthetic.* The examiner should observe that sterile technique is used to draw up the anaesthetic and, if the bottle is multi-dose, that sterility is maintained after the required amount has been drawn.
- (c) *Withdrawal of correct volume.* The trainee should draw up 3 mL if planning to do surgery on one eyelid, or 5 mL for two eyelids. No more than 5 mL of lidocaine should be used per eyelid in one operation, and the trainee should understand why this limit is important.
- (d) **Confirmation of the correct eyelid to receive anaesthetic.* This step is absolutely essential for a patient undergoing a unilateral procedure. With the surgeon at the head of the table looking across to the patient's feet, the side of the affected eyelid will be opposite compared to the side observed in the face-to-face examination. If the trainee is in error, the examiner should halt the procedure and note the performance as unsatisfactory.
- (e) *Safe use of the needle.* The examiner must observe the proper procedure, with the needle being introduced into the skin temporal to the lateral canthus and 3 mm above the eyelid margin. Insertion should be within the plane of the upper eyelid and parallel to the eyelid margin, with care being taken to assure that the needle tip does not exit the skin or enter the eye. The needle should never be directed towards the eyeball as this is unsatisfactory performance.
- (f) **Proper injection of the anaesthetic.* The needle should lie over the tarsal plate and in the plane of the eyelid. The trainee should continuously inject the anaesthetic ahead of advancing the needle.
- (g) *Establishing anaesthesia.* The local anaesthetic, 2 mL with the first injection, should be massaged into the eyelid for about one minute using a swab and gentle finger pressure against the orbital rim. Pressing against the eyeball should be avoided. After three minutes, the trainee should gently pinch the eyelid with forceps to ascertain whether the patient feels pain. If pain is felt, additional anaesthetic can be administered but no more than 5 mL should be given in total in any eyelid in one operation.

15.9. Bilamellar tarsal rotation procedure

- (a) **Proper clamp size selection and placement.* The examiner should observe the proper clamp size selection and its proper placement on the upper eyelid to be operated. The TT clamp is placed so that the eyelid margin lines up with the groove on the plate and then secured. The Waddell clamp is placed so that the eyelid margin is up against the vertical piece on the clamp and then secured. The trainee should be able to explain why correct size and placement is important.
- (b) **Correct position, depth and extent of incision.* The incision on the eyelid must be in the correct position, of the correct depth, and must extend the correct distance across the eyelid. The examiner should observe that the incision is parallel to the eyelid margin and about 3 mm above it. The incision should be full thickness and include all the eyelid layers and reach the clamp underneath. It should extend from one side of the clamp to the other with the blade held at right angles to the skin.
- (c) **Knowledge of possible complications and their management.* The trainee must show knowledge of at least the following three complications:
 - (i) *Damage to the globe from improper injection.* Keeping the needle parallel to the plane of the surface of the cornea is the best strategy. Damage could have catastrophic consequences; if it occurs, the eye should be patched and the patient referred immediately to an ophthalmologist.
 - (ii) *Excessive bleeding.* If the wound is bleeding, a pressure with a compress may stop the bleeding. If bleeding persists and is spurting arterial blood, the marginal artery may have been cut; it should be clamped, and a suture placed to stop the bleeding.
 - (iii) *Division of the eyelid margin.* With proper use of the clamp, this is nearly impossible. However, if it occurs, the cut portions must be sutured together appropriately before the operation proceeds further.
- (d) *Suturing*
 - (i) *Correct mounting of needles for suture placement.* The examiner must look for correct placement of the needle on the needle holder.
 - (ii) **Sutures correctly placed, aligned on eyelid margin and larger fragments.* The examiner looks for sutures having the correct depth and bite in the tissues. Sutures should be relatively equidistant, aligned to look straight, and avoid “gathering” of tissue; no suture should be more than 1 mm out of alignment.
- (e) *Tying sutures and evaluating outcome*
 - (i) **Tightening sutures.* The examiner observes the trainee doing a double throw of all three sutures followed by removal of the clamp. The trainee must tighten the double throws with sufficient tension to produce a slight overcorrection with eyelashes pointing away from the eyeball.

- (ii) **The trainee must evaluate the eyelid for under- or over-correction prior to completing the knots.* The trainee should be familiar with steps to correct either incorrect outcome prior to tying the knots.
- (iii) *Completing the knots.* Once the desired slight overcorrection is achieved, the examiner observes the trainee completing the knots with two single throws and cutting the sutures 3 mm above the knot.
- (iv) **Knowledge of how to manage gross over- or under-correction.* The trainee must know how to correct gross over- or under-correction. Overcorrection must be rectified postoperatively by repeating the suturing, tying the sutures with less tension to reduce the overcorrection as appropriate. Under-correction is corrected postoperatively by removing the original sutures and repeating the suturing, tying the sutures with greater tension to achieve slight overcorrection.
- (v) *Appropriate skin sutures (if applied).* The examiner looks for 1 mm bites, tied together gently.

15.10. Posterior lamellar tarsal rotation (modified Trabut) procedure

The checklist for the posterior lamellar tarsal rotation (modified Trabut) procedure **prior to commencing the surgery** is exactly the same as for the bilamellar tarsal rotation procedure.

- (a) **Proper placement of traction suture and eversion.* The examiner should observe proper placement of the traction suture. The traction suture is placed at about 3 mm above the lashes through the skin and orbicularis muscle by taking two 5 mm bites horizontally. The Trabut plate is used in conjunction with the traction suture and a haemostat to fix and keep the lid in an everted position. The examiner observes that the correct end (size) of the Trabut plate is used. The examiner should observe that the upper eyelid is well everted allowing for a good incision to be performed.
- (b) **Correct position, depth and extent of incision.* The incision on the eyelid must be in the correct position, of the correct depth, and must extend the correct distance across the eyelid. The examiner should observe that the incision is curvilinear and 3 mm from the eyelid margin and is done by holding the blade perpendicular to the conjunctiva, starting 2 mm lateral to the punctum and extending towards the lateral canthus. The incision should be through the conjunctiva and the tarsal plate but not through the muscle.
- (c) **Proper dissection of the eyelid margin and larger fragments.* The examiner should observe the trainee conducting blunt dissection of the eyelid fragments to create a pocket between the orbicularis and the tarsal plate of about 2–3 mm deep for the eyelid margin fragment and about 5 mm deep for the larger fragment.
- (d) **Knowledge of possible complications and their management.* The trainee must show knowledge of at least the following three complications:

- (i) *Damage to the globe from improper injection.* Keeping the needle parallel to the plane of the surface of the cornea is the best strategy. Damage could have catastrophic consequences; if it occurs, the eye should be patched and the patient referred immediately to an ophthalmologist.
 - (ii) *Excessive bleeding.* If the wound is bleeding, a pressure with a compress may stop the bleeding. If bleeding persists and is spurting arterial blood, the marginal artery may have been cut; it should be clamped and a suture placed to stop the bleeding.
 - (iii) *Division of eyelid margin.* If this occurs the cut margin must be sutured together appropriately before the operation proceeds further.
- (e) *Suturing*
- (i) *Correct mounting of needles for suture placement.* The examiner must look for correct placement of the needle on the needle holder.
 - (ii) **Sutures correctly placed and aligned on eyelid margin and larger fragments.* The examiner looks for sutures having the correct depth and bite in the tissues. Sutures should be relatively equidistant, aligned to look straight, and avoid “gathering” of tissue; no suture should be more than 1 mm out of alignment.
 - (iii) **Pulling the sutures.* The examiner notes that the trainee can easily guide the larger fragment into the pocket of the eyelid margin fragment.
- (f) *Tying sutures and evaluating outcomes*
- (i) **Tightening sutures.* The examiner observes the trainee doing a double throw of all three sutures followed by removal of the Trabut plate. The traction suture is kept in case re-suturing is needed. The trainee must tighten the double throws with sufficient tension to produce a slight overcorrection with eyelashes pointing away from the eyeball.
 - (ii) **The trainee must evaluate the eyelid for under- or over-correction prior to completing the knots.* The trainee should be familiar with steps to correct either incorrect outcome prior to tying the knots.
 - (iii) *Completing the knots.* Once the desired slight overcorrection is achieved, the examiner observes the trainee completing the knots with two single throws and cutting the sutures 3 mm above the knot. The examiner observes the removal of the traction suture.
 - (iv) **Knowledge of how to manage gross over- or under-correction.* The trainee must know how to correct gross over- or under-correction. The trainee should check for proper dissection of the distal and proximal fragments, and complete dissection if necessary. In the case of an undercorrection, the sutures should be reapplied in such a way that they are closer to the eyelid margin and tied firmly to produce the desired slight overcorrection. In the case of an overcorrection, the sutures should be reapplied in such a way that they are further from the eyelid margin and tied gently to produce the desired slight overcorrection.

15.11. Postoperative care

- (a) *Provision of appropriate postoperative care.* The examiner should observe the trainee cleaning the surgical area, applying ointment into the lower fornix and on to the wound, patching the eye with the eyelids closed, placing adhesive tape diagonally across the patch (avoiding the mouth) by applying slight pressure, and providing analgesic tablets and a single dose of oral azithromycin, if available.
- (b) *Giving post-operative instructions to the patient.* The trainee should advise the patient on postoperative care, telling the patient to keep the patch until the next day. The patient should be advised to return for evaluation the next day for removal of the patch and evaluation by the surgeon, and if necessary, suture removal after an appropriate interval. The trainee should advise the patient on proper wound care. Finally, the trainee should describe some of the complications, including excessive bleeding and pain, and persistent post-operative swelling that may indicate infection. The patient should be instructed to return if any of these develop.
- (c) **Knowledge of severe postoperative complications and their management.* The trainee should discuss with the examiner the complication of excessive bleeding and use of pressure to control it, as well as the possible need to reopen the wound. The trainee should be familiar with how to correct undercorrection or overcorrection on the first postoperative day. He or she should also discuss infection, the use of systemic antibiotics, signs of serious infection (cellulitis) and the need to refer the patient to a hospital if the problem does not resolve in 48–72 hours.
- (d) *Knowledge of managing granulomata.* If granulomata occur, the trainee should know how they are removed.

15.12. Use of the checklist

The examiner should use the checklist for each trainee. All items should be scored as satisfactory or unsatisfactory for the first operation, but some of the questions on knowledge can be excluded for the subsequent operations. At the end of the five operations, the examiner calculates the total number of unsatisfactory marks for both starred and unstarred items. Any unsatisfactory mark for any starred item in any one operation is sufficient to deny certification and send the trainee for further training. A total of 10 unsatisfactory marks in the other, unstarred, items across the five operations is also sufficient to deny certification. A total of six to nine unsatisfactory scores requires that the examiner discusses the problems with the trainee, and the examiner should consider having the trainee perform five additional operations with improving scores before certification can be achieved.

16. Checklist of procedures for certification of a surgeon in bilamellar tarsal rotation

Examiner: Please observe the trainee in all of the following procedures and indicate whether each procedure is performed satisfactorily (tick “S”) or unsatisfactorily (tick “U”). If the procedure is not performed, you must indicate “unsatisfactorily”, since none of these procedures can be omitted. Mark your observations at the end of each operation. At the end of all five operations, total the scores. Trainees **MUST** perform the procedures marked with a star (*) satisfactorily in order to be certified. Any unsatisfactory mark for any starred item in any one operation is sufficient to deny certification and send the trainee for further training. No unsatisfactory marks in the items with stars (*), and fewer than 10 unsatisfactory marks for all other unstarred items over all five operations, must be achieved for certification to be granted.

A total of 6–9 unsatisfactory scores should act as a warning: the examiner must discuss the problems with the trainee and consider having the trainee perform five additional operations with improving scores before certification can be achieved.

SURGEON'S NAME: _____

DATE: _____

EXAMINER'S NAME _____

Bilamellar tarsal rotation	Lid 1		Lid 2		Lid 3		Lid 4		Lid 5	
	OD/OS		OD/OS		OD/OS		OD/OS		OD/OS	
	S	U	S	U	S	U	S	U	S	U
Before surgery										
Setting up the surgical space										
Assembly of necessary materials before surgery										
Knowledge of surgical materials										
Sterilization of equipment before use										
* Knowledge of sterile techniques										
* Appropriate sterilization by autoclave or pressure cooker autoclave of all non-disposable instruments and materials										
* Handling of sterile instruments and items (e.g. using sterile gloves, forceps, towels)										
Examination of the patient										
Greeted the patient appropriately										
Used a bright torch and loupes to examine the eyelid										
Looked up at the eyelid from below to examine for TT and entropion										
* Correctly identified the presence or absence of TT and the presence or absence of entropion										
* Determined whether there was defective eyelid closure										
Obtained a relevant medical history from the patient										
* Correctly classified patient as a surgical patient										
Preoperative preparation										
Explained to the patient what was wrong and what was going to happen during the procedure										
Administered topical anaesthetic										
Put on a cap, mask and loupes										
Washed hands appropriately										
* Put on sterile gloves without contaminating them so as to maintain sterility										
* Prepared patient's face and eyelids using skin preparation solution (e.g. povidone iodine)										

Injecting anaesthetic										
Checked the bottle label										
Anaesthetic kept sterile										
Drew up correct volume of anaesthetic (i.e. not more than 5 mL of lidocaine for two eyelids)										
* Re-checked that correct eye was receiving anaesthetic										
Needle inserted properly – never pointed perpendicular to the eyelid skin										
* Anaesthetic injected properly into eyelid										
Anaesthesia ascertained by checking patient's response to pain										
Operation										
* Proper TT or Waddell clamp size selection and placement										
* Incision on eyelid correctly positioned and of correct depth and extent										
* Knowledge of possible operative complications and their management										
Information on progress of surgery given to patient; ensured patient was comfortable and well; reacted promptly to patient's needs										
Needle inserted properly – never pointed perpendicular to the eyelid skin										
* Sutures correctly placed (correct depth and bite in tissues) and aligned on eyelid margin and larger fragments										
Tying sutures and evaluating outcome										
* Double-throws pulled with sufficient firmness after removal of clamp to produce slight overcorrection, eyelashes pointed away from eye										
* Evaluation of under or overcorrection before completing knots										
Completed the knots with two single throws										
* Knowledge of management of gross over- or under-correction										
Skin sutures appropriate										
Postoperative care										
Appropriate postoperative care given (e.g. cleaning, ointment, dressings, analgesics, azithromycin)										
Adequate postoperative advice given to the patient										
* Knowledge of severe postoperative complications and their management										
Knowledge of management of granulomata										

SCORE: No. of unsatisfactory* items _____ No. of other unsatisfactory items _____

Bilamellar Tarsel Rotation

COMMENTS BY EXAMINER:

17. Checklist of procedures for certification of a surgeon in posterior lamellar tarsal rotation (modified Trabut)

Examiner: Please observe the trainee in all the following procedures and indicate whether the procedure is performed satisfactorily (tick “S”) or unsatisfactorily (tick “U”). If the procedure is not performed, you must indicate “unsatisfactorily”, since none of these procedures can be omitted. Mark your observations at the end of each operation. At the end of all five operations, total the scores. Trainees **MUST** perform the procedures marked with a star (*) satisfactorily in order to be certified. Any unsatisfactory mark for any starred item in any one operation is sufficient to deny certification and send the trainee for further training. No unsatisfactory marks in the items with stars (*), and fewer than 10 unsatisfactory marks for all other items over all five operations must be achieved for certification to be granted.

A total of 6–9 unsatisfactory scores requires that the examiner discusses the problems with the trainee and the trainee and consider having the trainee perform five additional operations with improving scores before certification can be achieved.

SURGEON'S NAME: _____

DATE: _____

EXAMINER'S NAME: _____

Posterior lamellar tarsal rotation (modified Trabut)	Lid 1 OD/OS		Lid 2 OD/OS		Lid 3 OD/OS		Lid 4 OD/OS		Lid 5 OD/OS	
	S	U	S	U	S	U	S	U	S	U
Before surgery										
Setting up the surgical space										
Assembly of necessary materials before surgery										
Knowledge of surgical materials										
Sterilization of equipment before use										
* Knowledge of sterile techniques										
* Appropriate sterilization by autoclave or pressure cooker autoclave of all non-disposable instruments and materials										
* Handling of sterilized instruments and items (e.g. using sterile gloves, forceps, towels)										
Examination of the patient										
Greeted the patient appropriately										
Used a bright torch to examine the eyelid										
Looked up at the eyelid from below to examine for TT and entropion										
* Correctly identified the presence or absence of TT and the presence or absence of entropion										
* Determined whether there was defective eyelid closure										
Obtained a relevant medical history from the patient										
* Correctly classified patient as a surgical patient										
Preoperative preparation										
Explained to the patient what was wrong and what was going to happen during the procedure										
Administered topical anaesthetic										
Put on a cap, mask and loupes										
Washed hands appropriately										
* Put on sterile gloves without contaminating them so as to maintain sterility										
* Prepared patient's face and eyelids using skin preparation solution (e.g. povidone iodine)										

Injecting anaesthetic										
Checked the bottle label										
Anaesthetic kept sterile										
Drew up correct volume of anaesthetic (i.e. not more than 5 mL of lidocaine for two eyelids)										
* Re-checked that correct eye was receiving anaesthetic										
Needle inserted properly – never perpendicular to eyelid skin										
* Anaesthetic injected properly into eyelid										
Anaesthesia ascertained by checking patient's response to pain										
Operation										
* Proper placement of traction suture, eversion of the eyelid and stabilization										
* Incision on conjunctiva and tarsal plate correctly positioned, and of appropriate depth and length										
* Proper dissection of eyelid and larger fragments										
* Knowledge of possible operative complications and their management										
Information on progress of surgery given to patient; ensured patient was comfortable and well; reacted promptly to patient's needs										
Suturing										
Needles correctly mounted for suture placement										
* Sutures correctly placed (correct depth and bite in tissues) and aligned on eyelid margin and larger fragments										
* Pulling in sutures, using forceps or bottom of a blade handle to guide larger fragment tarsus into pocket										
Tying sutures and evaluating outcome										
*Double-throws pulled with sufficient firmness after removal of the Trabut plate but keeping the traction suture to produce slight overcorrection, eyelashes pointed away from eye										
*Evaluation of under or overcorrection before completing knots										
Completed the knots with two single throws										
*Knowledge of management of gross over- or under- correction										
Postoperative care										
Appropriate postoperative care given (e.g. cleaning, ointment, dressings, analgesics, azithromycin)										
Adequate postoperative advice given to the patient										
* Knowledge of severe postoperative complications and their management										
Knowledge of management of granulomata										

SCORE: No. of unsatisfactory* items _____ No. of other unsatisfactory items _____

Posterior lamellar tarsal rotation (modified Trabut)

COMMENTS BY EXAMINER:

Bibliography

Alemayehu W, Melese M, Bejiga A, Worku A, Kebede W, Fantaye D. Surgery for trichiasis by ophthalmologists versus integrated eye care workers: a randomized trial. *Ophthalmology*. 2004;111(3):578–84. PMID: 15019339.

Bog H, Yorston D, Foster A. Results of community-based eyelid surgery for trichiasis due to trachoma. *Br J Ophthalmol*. 1993;77(2):81–3. PMID: 8435423.

Gower EW, West SK, Harding JC, Cassard SD, Munoz BE, Othman MS, et al. Trichomatous trichiasis clamp vs standard bilamellar tarsal rotation instrumentation for trichiasis surgery: results of a randomized clinical trial. *JAMA Ophthalmol*. 2013;131(3):294–301. PMID: 23494035.

Merbs SL, Kello AB, Gelema H, West SK, Gower EW. The trichomatous trichiasis clamp: a surgical instrument designed to improve bilamellar tarsal rotation procedure outcomes. *Arch Ophthalmol*. 2012;130(2):220–3. PMID: 22332216.

Rajak SN, Habtamu E, Weiss HA, Kello AB, Gebre T, et al. Absorbable versus silk sutures for surgical treatment of trichomatous trichiasis in Ethiopia: A randomised controlled trial. *PLoS Med* 2011; 8(12):e1001137. PMID: 22180732.

Reacher M, Foster A, Huber J & WHO Programme for the Prevention of Blindness. Trichiasis surgery for trachoma: the bilamellar tarsal rotation procedure. Geneva: World Health Organization; 1993 (<https://apps.who.int/iris/handle/10665/62064>).

Reacher MH, Muñoz B, Alghassany A, Daar AS, Elbualy M, Taylor HR. A controlled trial of surgery for trichomatous trichiasis of the upper lid. *Arch Ophthalmol*. 1992;110(5):667–74. PMID: 1580842.

Solomon AW, Kello AB, Bangert M, West SK, Taylor HR, Tekeraoi R, et al. The simplified trachoma grading system, amended. *Bull World Health Organ*. 2020;98(10):698–705. PMID: 33177759.

West SK, West ES, Alemayehu W, Melese M, Munoz B, Imeru A, et al. Single-dose azithromycin prevents trichiasis recurrence following surgery: randomized trial in Ethiopia. *Arch Ophthalmol*. 2006;124(3):309–14. PMID: 16534049.

Report of the 4th global scientific meeting on trachoma, Geneva, 27–29 November 2018. Geneva: World Health Organization; 2019 (<https://iris.who.int/handle/10665/325121>)

For further information, contact:

Global Neglected Tropical Diseases Programme
World Health Organization
20 avenue Appia
CH-1211 Geneva-27
Switzerland

<https://www.who.int/teams/control-of-neglected-tropical-diseases>

